

Alteration of plasma von Willebrand factor in the treatment of retinal vein occlusion with cystoid macular edema

Short title: Plasma von Willebrand factor in retinal vein occlusion with macular edema

Hiromasa Hirai¹, Mariko Yamashita², Masanori Matsumoto³, Takeyuki Nishiyama¹, Daishi Wada¹, Naoko Okabe¹, Yutaro Mizusawa¹, Hironobu Jimura¹, Tetsuo Ueda¹, Nahoko Ogata^{1*}

¹Department of Ophthalmology, Nara Medical University, Kashihara, Japan

Phone: +81-744-29-8884 (ext.3433), Fax: +81-744-23-8032

Email: hirai-masa@naramed-u.ac.jp (H.H.), k158380@naramed-u.ac.jp (T.N.),

d.wada@naramed-u.ac.jp (D.W.), naoko0811@naramed-u.ac.jp (Naoko

Okabe), urotauyuwasazumi@naramed-u.ac.jp (Y.M.), j-hiro@naramed-u.ac.jp

(H.J.), tueda@naramed-u.ac.jp (U.T.)

²Department of Ophthalmology, Nara City Hospital, Nara, Japan

Phone: +81-742-24-1251, Fax: +81-744-22-2478

Email: marko.yamashita@gmail.com (M.Y.)

18 ³Department of Blood Transfusion Medicine, Nara Medical

19 University, Kashihara, Japan

20 Phone: +81-744-22-3051, Fax: +81-744-29-0771

21 E-mail: mmatsumo@naramed-u.ac.jp (M.M.)

22

23 *Corresponding author

24 E-mail: ogata@naramed-u.ac.jp ([Nahoko Ogata](#))

25

Abstract

Retinal vein occlusion (RVO) is a major retinal disease accompanied by venous thrombosis. Although several studies have proposed an association between venous thrombosis and von Willebrand factor (VWF), the association between RVO and VWF remains unclear. We aimed to investigate the association between RVO and VWF and the alteration of VWF levels under the anti-vascular endothelial growth factor (VEGF) treatment. We enrolled 55 patients with RVO involved cystoid macular edema. They received intravitreal injection of anti-VEGF drugs, either ranibizumab or aflibercept. We examined the clinical data, measured plasma VWF: antigen (VWF: Ag) and plasma a disintegrin and metalloproteinase with a thrombospondin type 1 motif, member 13 (ADAMTS13) activity (ADAMTS13: AC) and analyzed them to identify variabilities during the treatment. At the baseline there was no significant difference between the RVO group and age-matched controls in both VWF: Ag and ADAMTS13: AC levels but ADAMTS13:AC was significantly lower in central RVO (CRVO) than in branch RVO (BRVO) ($P = 0.015$). In BRVO, the negative correlation was found between VWF: Ag and central choroidal thickness (CCT) ($r = -0.51$, $P < 0.001$). In BRVO after the anti-VEGF treatment, VWF: Ag

44 decreased significantly from 134% at the baseline to 109% at 1 day after ($P =$
 45 0.002) and to 107% at 1 month after ($P = 0.030$). In contrast, ADAMTS13: AC
 46 showed no significant difference during this period. In BRVO at 1 month after
 47 treatment, we found a negative correlation between VWF: Ag and CCT ($r =$
 48 -0.47 , $P = 0.001$). Our findings suggest an association between VWF and CCT
 49 in patients with BRVO, thus the measurement of VWF may be useful for
 50 evaluating the disease activity and prognosis.

51

Introduction

Von Willebrand factor (VWF), a large glycoprotein synthesized and secreted from vascular endothelial cells, acts as bridging molecule which adheres platelets to the injured vessels and stabilizes coagulation factor VIII [1]. VWF is specifically cleaved by disintegrin and metalloproteinase with a thrombospondin type 1 motif, member 13 (ADAMTS13) [2]. The balance between VWF and ADAMTS13 maintains the hemostatically coagulative function of the whole body. The release of VWF is known to increase with endothelial cell damage and elevated plasma VWF levels are usually observed in patients with hypertension and atherosclerosis [3–5]. Karaca et al. reported an association between plasma VWF and the severity of hypertensive retinopathy [6]. In other ocular diseases, elevated plasma VWF antigen (VWF: Ag) has been reported in age-related macular degeneration (AMD), and multimeric VWF has been found in pachychoroid neovascularopathy [7–9].

Several studies have also reported that increased plasma VWF levels are associated with thrombotic complications [10–12]. Interestingly, this association includes not only atherothrombotic diseases (such as myocardial infarction or ischemic stroke) but also venous thrombosis. Edvardsen et al. recently

suggested an association between VWF and venous thrombosis, such as deep vein thrombosis and pulmonary embolism [12].

Retinal vein occlusion (RVO) is a major retinal disease that causes retinal hemorrhage and severe vision loss [13,14]. Vision loss in RVO is mainly due to cystoid macular edema (CME). RVO is a multifactorial disease with several risk factors, including age, hypertension, arteriosclerosis, diabetes mellitus, dyslipidemia, high blood viscosity, and thrombosis [14,15]. RVO can be classified into two types: branch RVO (BRVO) and central RVO (CRVO). In BRVO, although partial retinal ischemia may occur, blood perfusion throughout the retina is generally maintained [16]. Alternatively, the entire retina can become severely ischemic in CRVO, which leads to severe vision loss and neovascular glaucoma [17]. Usually, CRVO has a worse prognosis than BRVO. In patients with RVO, it is important to understand the retinal circulatory status to control the disease.

Intravitreal injection of anti-vascular endothelial growth factor (VEGF) drugs has been widely used for the treatment of RVO with CME. However, CME often recurs and requires additional injections. The systemic side effects of anti-VEGF vitreous injection remain controversial. Several studies have reported

thromboembolic events, including myocardial infarction and ischemic stroke

[18,19].

In addition, anti-VEGF antibodies are known to enter the systemic circulation,

decrease VEGF levels and affect other cytokines in the plasma [20]. We have

already demonstrated that VWF: Ag levels were decreased after intravitreal

aflibercept injection in patients with AMD [8].

Although RVO is accompanied by venous thrombosis, few clinical studies have

examined the association between VWF and RVO and these studies have

reported different results. Thus, the levels of VWF in RVO remain controversial

[21–23]. Furthermore, no study has investigated whether plasma VWF is

influenced by anti-VEGF vitreous injection in patients with RVO.

In this study, we aimed to investigate the involvement of VWF in the

pathogenesis of RVO and its variability after anti-VEGF injection.

Methods

This prospective study was conducted at Nara Medical University Hospital,

Kashihara City, Nara Prefecture, Japan, from June 2014 to March 2020. This

study protocol was approved by the medical research ethics committee of Nara

Medical University and followed the Declaration of Helsinki. We confirmed that all methods were performed in accordance with the relevant guidelines and regulations. All patients provided written informed consent for participation in the study. Fifty-five patients diagnosed as RVO with CME who were aged 51 to 91 years and age-matched control subjects (patients before cataract surgery) were enrolled in this study. Patients who had severe systemic complications or did not receive anti-VEGF drugs, that is selected other treatments, were excluded.

RVO was diagnosed based on ophthalmological findings, slit lamp examination, fundus examination, optical coherence tomography, wide-angle fundus photography, and fluorescein angiography. We also examined best-corrected visual acuity (BCVA, LogMAR unit), central retinal thickness (CRT), and central choroidal thickness (CCT). The pathological classification (BRVO or CRVO) was judged independently by two researchers based on the examinations.

All patients received intravitreal injections of anti-VEGF drugs, either ranibizumab (Lucentis; Novartis International AG, Basel, Switzerland) or aflibercept (Eylea; Bayer HealthCare Pharmaceuticals, Berlin, Germany) at a dose of 2.0 mg/0.05 mL. The drugs were selected by the attending physicians.

The intravitreal injection was approached 3.5–4.0 mm posterior to the corneal limbus.

Whole blood was collected by venipuncture of the anterior arm into a tube containing 3.8% trisodium citrate (1:9). Blood samples were collected four times: before treatment (first visit), 1 day after treatment, 1 week after treatment, and 1 month after treatment. All plasma samples were stored at -80°C and thawed at 37°C prior to examination.

We measured plasma VWF: Ag levels using sandwich enzyme-linked immunosorbent assay (ELISA), rabbit anti-human VWF polyclonal antiserum (DAKO, Glostrup, Denmark) [24], and plasma ADAMTS13 activity (ADAMTS13: AC) by chromogenic ADAMTS13 activity ELISA (Kainos, Tokyo, Japan) [25].

We defined the 100% reference value as the amount of VWF: Ag and ADAMTS13: AC in pooled normal plasma from 20 volunteers (10 men and 10 women) aged between 20 and 40 years.

All statistical analyses were performed using EZR (Saitama Medical Center, Jichi Medical University, Saitama, Japan), a graphical user interface for R (The R Foundation for Statistical Computing, Vienna, Austria) [26]. We used t-tests to compare two continuous variables (such as age) and Fisher's exact tests to

compare the proportions of categorical variables (such as sex) between the groups. We also used the Friedman and Wilcoxon signed-rank tests to compare the four continuous variables (VWF: Ag). Correlations were evaluated using Pearson's correlation coefficient. The threshold for significance was set at $P < 0.05$.

Results

The characteristics of the patients with RVO and controls are summarized in Table 1. In patients with RVO, the median age was 73.0 years, and 33 (60%) were male. Twenty-seven (49%) patients had hypertension. There was no significant difference in VWF: Ag and ADAMTS13: AC between the RVO group and the controls ($P = 0.70$ and $P = 0.22$, respectively). We also examined the baseline characteristics of patients with RVO classified according to RVO type, BRVO and CRVO. Both CRT and CCT were significantly thicker in CRVO than in BRVO ($P = 0.013$ and 0.045 , respectively). The number of dyslipidemia cases was also significantly higher in CRVO than in BRVO ($P = 0.004$). Although VWF: Ag showed no significant difference between the two groups ($P = 0.18$), ADAMTS13:AC was significantly lower in CRVO than in BRVO ($P =$

0.015). In other categories, there were no significant differences between the two groups.

We assessed the blood type because the blood O group had lower plasma VWF: Ag levels than the other groups [27]. There was no difference in the blood type between the two groups.

178

179

Table 1: Basic characteristics of RVO patients and control

	Total RVO (n=55)	Control (n=96)	<i>P</i> value	BRVO (n=43)	CRVO (n=12)	<i>P</i> value
Age, median (IQR)	73.0 (65.0-79.0)	74.0 (69.0-80.0)	0.18†	73.0 (66.0-79.5)	72.0 (64.0-74.3)	0.33†
Sex (male), n (%)	33 (60)	52 (54)	0.50‡	23 (53)	10 (83)	0.10‡
BCVA, median (IQR),	0.40 (0.15-0.52)	—		0.30 (0.15-0.52)	0.40 (0.28-0.57)	0.19†
CRT (μm), median (IQR)	477 (357-614)	—		440 (343-586)	574 (491-747)	0.013†
CCT (μm), median (IQR)	238 (197-264)	—		235 (180-259)	257 (214-298)	0.045†
Hypertension, n (%)	27 (49)	—		20 (47)	7 (58)	0.53‡
Dyslipidemia, n (%)	13 (24)	—		6 (14)	7 (58)	0.004‡
Diabetes, n (%)	6 (11)	—		4 (9)	2 (17)	0.60‡
Cardiovascular disease, n (%)	8 (15)	—		6 (14)	2 (17)	1‡
VWF (%), median (IQR)	134 (92-173)	130 (109-167)	0.70†	139 (107-175)	92 (60-122)	0.18†
ADAMTS13 (%), median (IQR)	45 (33-61)	54 (45-63)	0.22†	51 (38-69)	34 (29-39)	0.015†
Blood Type, n (%)						
Type O	18 (33)	32 (33)	1‡	12 (28)	6 (50)	0.18‡
Type A	23 (42)	34 (35)	0.49‡	19 (44)	4 (33)	0.74‡
Type B	9 (16)	16 (17)	1‡	9 (21)	0 (0)	0.18‡
Type AB	5 (9)	14 (15)	0.45‡	3 (7)	2 (17)	0.30‡

RVO, retinal vein occlusion

IQR, interquartile range

BRVO, branch retinal vein occlusion

CRVO, central retinal vein occlusion

BCVA, best-corrected visual acuity (LogMAR unit)

CRT, central retinal thickness

CCT, central choroidal thickness

VWF, Von Willebrand factor

† t test

‡ fisher's exact test

180

181

182

183

184

185

186

187

188

189 Fig. 1 shows the correlation between VWF: Ag and each parameter at the
190 baseline. In BRVO, there was a positive correlation between VWF: Ag and CRT
191 ($r = 0.30$, $P = 0.049$). We also found a strong negative correlation between
192 VWF: Ag and CCT ($r = -0.51$, $P < 0.001$). In CRVO, no correlations were found
193 in any of the categories.

194

195 **Fig. 1. The correlation between VWF: Ag and parameters (BCVA, CRT, and**
196 **CCT) at the baseline.** In each graph, the horizontal axis presents the VWF: Ag
197 (%). VWF: Ag, plasma VWF: antigen; BCVA, best-corrected visual acuity
198 (LogMAR unit); CRT, central retinal thickness; CCT, central choroidal thickness.

199

200 Table 2 shows the basic characteristics of patients with RVO classified
201 according to the selected anti-VEGF drugs. We confirmed that there were no
202 significant differences between the two groups.

203

204

205

Table 2: Basic characteristics of patients classified by anti VEGF drugs

	Aflibercept (n=28)	Ranibizumab (n=27)	<i>P</i> value
Age, median (IQR)	74.0 (66.0-79.0)	72.0 (63.5-78.0)	0.78†
Sex (male), n (%)	15 (54)	18 (67)	0.41‡
RVO type (BRVO / CRVO)	21 / 7	22 / 5	0.75‡
BCVA, median (IQR)	0.22 (0.14-0.52)	0.39 (0.26-0.61)	0.17†
CRT (µm), (IQR)	456 (358-626)	481 (371-586)	1†
CCT (µm), (IQR)	233 (199-257)	251 (187-278)	0.58†
VWF (%), median (IQR)	118 (82-164)	139 (111-183)	0.54†
ADAMTS13 (%), median (IQR)	40 (31-53)	51 (34-69)	0.67†

IQR, interquartile range

BRVO, branch retinal vein occlusion

CRVO, central retinal vein occlusion

BCVA, best-corrected visual acuity (LogMAR unit)

CRT, central retinal thickness

CCT, central choroidal thickness

VWF, Von Willebrand factor

† t test ‡ Fisher's exact test

Table 3 shows the alterations of clinical data in patients with RVO by treatment.

In total RVO, BCVA significantly improved from 0.40 at the baseline to 0.22 at 1 month after anti-VEGF treatment ($P < 0.001$). Both CRT and CCT were significantly thinner at 1 month after treatment ($P < 0.001$ and 0.001 , respectively). In BRVO, BCVA also significantly improved from 0.35 at the baseline to 0.15 at 1 month after treatment ($P < 0.001$). Both CRT and CCT were significantly thinner at 1 month after treatment ($P < 0.001$ and $P = 0.003$, respectively). In CRVO, BCVA significantly improved from 0.40 at the baseline to 0.35 at 1 month after treatment ($P = 0.004$). CRT was significantly thinner at 1 month after treatment ($P < 0.001$), whereas there was no significant difference in CCT ($P = 0.24$).

Table 3: Alterations of clinical data in patients with RVO by treatments

	Total RVO (n=55)		<i>P</i> value	BRVO (n=43)		<i>P</i> value	CRVO (n=12)		<i>P</i> value
	Baseline	1 month		Baseline	1 month		Baseline	1 month	
BCVA, median	0.40	0.22	< 0.001†	0.35	0.15	< 0.001†	0.40	0.35	0.040†
(IQR)	(0.15-0.52)	(0.05-0.40)		(0.15-0.52)	(0.05-0.46)		(0.28-0.57)	(0.21-0.40)	
CRT(μm), median	477	224	< 0.001†	440	222	< 0.001†	574	239	<0.001†
(IQR)	(357-614)	(199-251)		(343-586)	(196-244)		(491-747)	(219-258)	
CCT (μm), median	238	215	0.001†	235	213	0.003†	257	242	0.24†
(IQR)	(197-264)	(174-270)		(180-259)	(160-267)		(214-298)	(204-290)	

IQR, interquartile range

BRVO, branch retinal vein occlusion

CRVO, central retinal vein occlusion

BCVA, best-corrected visual acuity (LogMAR unit)

CRT, central retinal thickness

CCT, central choroidal thickness

† paired t test

232

233

Fig. 2 shows the correlation between VWF: Ag and each parameter 1 month after anti-VEGF treatment. In BRVO, we found a negative correlation between VWF: Ag and CCT ($r = -0.47$, $P = 0.001$). In CRVO, no correlations were found in any of the categories.

Fig. 2. The correlation between VWF: Ag and parameters (BCVA, CRT, and CCT) 1 month after anti-VEGF treatment. In each graph, the horizontal axis presents the VWF: Ag (%). VWF: Ag, plasma VWF: antigen; BCVA, best-corrected visual acuity (LogMAR unit); CRT, central retinal thickness; CCT, central choroidal thickness.

Fig. 3 shows the time course of VWF: Ag in patients with total RVO, BRVO, and CRVO. In total RVO, VWF: Ag decreased significantly from 134% at the baseline to 104% at 1 day after treatment ($P = 0.002$). In BRVO, VWF: Ag also showed a significant reduction from 139% at baseline to 113% at 1 day after treatment ($P = 0.002$) and to 98% at 1 month after treatment ($P = 0.030$). However, in CRVO, VWF: Ag showed no significant difference during this period. ADAMTS13: AC showed no significant difference during the study

252 period in all categories.

253

254 **Fig 3. Alterations of VWF: Ag after anti-VEGF treatment (* < 0.05, ** < 0.01).**

255 Each of the values above the graph presents the median with the interquartile

256 range.

Discussion

This study investigated the coagulation-related factors in patients with RVO at the baseline and their alterations during the treatment.

According to our results, there was no significant difference in plasma VWF between the RVO and age-matched controls at the baseline. Several researchers have reported that plasma VWF increased not only in patients with hypertension and arteriosclerosis but also in healthy individuals with aging [28,29].

ADAMTS13:AC was significantly lower in CRVO than in BRVO at the baseline. Interestingly, the number of dyslipidemia cases was significantly higher in CRVO than in BRVO. ADAMTS13 is mainly synthesized in hepatic stellate cells [2]. Thus the liver cells in patients with dyslipidemia would be damaged by fat deposition, then production of ADAMTS13 could be decreased in patients with CRVO.

Although it was not statistically significant, the VWF levels in BRVO were higher than those in CRVO. BRVO is accompanied by a thrombus at the arteriovenous crossing point where the retinal artery and vein share an outer sheath [30,31], therefore the arterial pressure directly cause thrombosis. Alternatively, CRVO is

accompanied by a thrombus in the central retinal vein where it passes through the lamina cribrosa within the optic nerve. A recent study focusing on BRVO and CRVO has shown that atherosclerosis is a more inducing factor for developing BRVO than that for CRVO [32]. High levels of plasma VWF in our study suggest the atherosclerosis in BRVO.

We also compared VWF levels and each ophthalmologic parameters of RVO and found a significant negative correlation between VWF: Ag and CCT in BRVO at the baseline. Although studies examining the association between VWF and choroidal thickness are few, Gifford et al. reported an inverse association between choroidal thickness and VWF in patients with liver cirrhosis [33]. Many previous reports demonstrated that choroidal thickness in patients with RVO decreases after intravitreal injection of anti-VEGF drugs [34].

Sakanishi et al. reported that the recurrence of CME was significantly few in cases with choroidal thinning after treatment [35]. Thus, CCT may reflect the treatment effect and prognosis in RVO. Interestingly, a significant negative correlation between VWF: Ag and CCT was still observed 1 month after anti-VEGF injection in BRVO. Therefore, the measurement of VWF: Ag during the treatment may be useful in evaluating the disease activity of BRVO. VWF: Ag

also showed significant alterations under anti-VEGF treatment, especially in BRVO. Several researchers have previously proposed the association between VWF and VEGF [36,37]. VWF is secreted from endothelial-specific organelles, called Weibel palade bodies (WPBs) which widely distribute in the systemic vessels [2]. VEGF activates exocytosis of WPBs, resulting in the release of VWF [37,38] which activates VEGF-R2 signaling and may promote angiogenesis [39]. Although few studies have examined the association between anti-VEGF drugs and VWF, Pace et al. reported decreased VWF plasma levels after anti-VEGF treatment (bevacizumab) in recurrent glioma [40]. We also report the VWF reduction after anti-VEGF treatment in patients with BRVO. Thus, the alterations of VWF may reflect the therapeutic effect after anti-VEGF drug administration in BRVO.

This study has some limitations. First, this was a cross-sectional study with a relatively small sample size. A larger number of patients will be required for more accurate analyses. Second, we only assessed patients who received anti-VEGF drugs. It might be necessary to compare VWF levels in patients with and without treatment at the same time course. However, it is difficult to analyze untreated patients through frequent medical visits. Finally, we did not evaluate

the long-term effects of anti-VEGF drugs for more than 1 month after intravitreal injection. A longer follow-up period is required to confirm these results.

Conclusion

In summary, we performed prospective analyses on VWF in patients with RVO during the treatment and found unique characteristics. Our findings suggest an association between VWF and CCT in BRVO, thus the measurement of VWF may be useful for evaluating the disease activity and prognosis.

Acknowledgements

The authors thank Hiroki Tsujinaka for his useful discussions and Editage (www.editage.com) for English language editing.

References

1. Sadler JE. Biochemistry and genetics of von Willebrand factor. Annu Rev Biochem. 1998;67: 395-424. doi: [10.1146/annurev.biochem.67.1.395](https://doi.org/10.1146/annurev.biochem.67.1.395), PubMed PMID: [9759493](https://pubmed.ncbi.nlm.nih.gov/9759493/).
2. Crawley JT, de Groot R, Xiang Y, Luken BM, Lane DA. Unraveling the scissile bond: how ADAMTS13 recognizes and cleaves von Willebrand factor. Blood. 2011;118: 3212-3221. doi: [10.1182/blood-2011-02-306597](https://doi.org/10.1182/blood-2011-02-306597), PubMed PMID: [21715306](https://pubmed.ncbi.nlm.nih.gov/21715306/), PubMed Central PMCID: [PMC3179391](https://pubmed.ncbi.nlm.nih.gov/PMC3179391/).
3. Blann AD, Naqvi T, Waite M, McCollum CN. Von Willebrand factor and endothelial damage in essential hypertension. J Hum Hypertens. 1993;7: 107-111. PubMed PMID: [8510081](https://pubmed.ncbi.nlm.nih.gov/8510081/).
4. Blann AD, McCollum CN. Von Willebrand factor, endothelial cell damage and atherosclerosis. Eur J Vasc Surg. 1994;8: 10-15. doi: [10.1016/s0950-821x\(05\)80112-4](https://doi.org/10.1016/s0950-821x(05)80112-4), PubMed PMID: [8307205](https://pubmed.ncbi.nlm.nih.gov/8307205/).
5. Lip GY, Blann A. Von Willebrand factor: a marker of endothelial dysfunction in vascular disorders? Cardiovasc Res. 1997;34: 255-265. doi: [10.1016/s0008-6363\(97\)00039-4](https://doi.org/10.1016/s0008-6363(97)00039-4), PubMed PMID: [9205537](https://pubmed.ncbi.nlm.nih.gov/9205537/).
6. Karaca M, Coban E, Ozdem S, Unal M, Salim O, Yucel O. The association

347 between endothelial dysfunction and hypertensive retinopathy in essential
348 hypertension. Med Sci Monit. 2014;20: 78-82. Epub: 78–82. doi:
349 [10.12659/MSM.889659](https://doi.org/10.12659/MSM.889659), PubMed PMID: [24441931](https://pubmed.ncbi.nlm.nih.gov/24441931/), PubMed Central PMCID:
350 [PMC3907530](https://pubmed.ncbi.nlm.nih.gov/PMC3907530/).

351 7. Lip PL, Blann AD, Hope-Ross M, Gibson JM, Lip GY. Age-related macular
352 degeneration is associated with increased vascular endothelial growth factor,
353 hemorheology and endothelial dysfunction. Ophthalmology. 2001;108: 705-710.
354 doi: [10.1016/s0161-6420\(00\)00663-1](https://doi.org/10.1016/s0161-6420(00)00663-1), PubMed PMID: [11297487](https://pubmed.ncbi.nlm.nih.gov/11297487/).

355 8. Yamashita M, Matsumoto M, Hayakawa M, Sakai K, Fujimura Y, Ogata N.
356 Intravitreal injection of aflibercept, an anti-VEGF antagonist, down-regulates
357 plasma von Willebrand factor in patients with age-related macular degeneration.
358 Sci Rep.: 2018: 8(1):1491. doi: [10.1038/s41598-018-19473-0](https://doi.org/10.1038/s41598-018-19473-0), PubMed PMID:
359 [29367644](https://pubmed.ncbi.nlm.nih.gov/29367644/), PubMed Central PMCID: [PMC5784081](https://pubmed.ncbi.nlm.nih.gov/PMC5784081/).

360 9. Hirai H, Yamashita M, Matsumoto M, Hayakawa M, Sakai K, Ueda T, et al.
361 Analysis focusing on plasma von Willebrand factor in pachychoroid
362 neovasculopathy and age-related macular degeneration. Sci Rep.: 2021:
363 11(1):19987. Epub: 20211007. doi: [10.1038/s41598-021-99557-6](https://doi.org/10.1038/s41598-021-99557-6), PubMed
364 PMID: [34620972](https://pubmed.ncbi.nlm.nih.gov/34620972/), PubMed Central PMCID: [PMC8497477](https://pubmed.ncbi.nlm.nih.gov/PMC8497477/).

- 365 10. Buchtele N, Schwameis M, Gilbert JC, Schörghofer C, Jilma B. Targeting
366 von Willebrand factor in ischaemic stroke: focus on clinical evidence. Thromb
367 Haemost. 2018;118: 959-978. doi: [10.1055/s-0038-1648251](https://doi.org/10.1055/s-0038-1648251), PubMed PMID:
368 [29847840](https://pubmed.ncbi.nlm.nih.gov/29847840/), PubMed Central PMCID: [PMC6193403](https://pubmed.ncbi.nlm.nih.gov/PMC6193403/) established to discover and
369 develop novel biotherapeutics targeting von Willebrand factor. Other authors
370 declare no conflict of interest.
- 371 11. Spiel AO, Gilbert JC, Jilma B. Von Willebrand factor in cardiovascular
372 disease: focus on acute coronary syndromes. Circulation. 2008;117: 1449-
373 1459. doi: [10.1161/CIRCULATIONAHA.107.722827](https://doi.org/10.1161/CIRCULATIONAHA.107.722827), PubMed PMID: [18347221](https://pubmed.ncbi.nlm.nih.gov/18347221/).
- 374 12. Edvardsen MS, Hindberg K, Hansen ES, Morelli VM, Ueland T, Aukrust P,
375 et al. Plasma levels of von Willebrand factor and future risk of incident venous
376 thromboembolism. Blood Adv. 2021;5: 224-232. doi:
377 [10.1182/bloodadvances.2020003135](https://doi.org/10.1182/bloodadvances.2020003135), PubMed PMID: [33570640](https://pubmed.ncbi.nlm.nih.gov/33570640/), PubMed
378 Central PMCID: [PMC7805310](https://pubmed.ncbi.nlm.nih.gov/PMC7805310/).
- 379 13. Li J, Paulus YM, Shuai Y, Fang W, Liu Q, Yuan S. New developments in the
380 classification, pathogenesis, risk factors, natural history, and treatment of
381 branch retinal vein occlusion. J Ophthalmol. 2017;2017: 4936924. doi:
382 [10.1155/2017/4936924](https://doi.org/10.1155/2017/4936924), PubMed PMID: [28386476](https://pubmed.ncbi.nlm.nih.gov/28386476/), PubMed Central PMCID:

- 383 [PMC5366235](#).
- 384 14. Yasuda M, Kiyohara Y, Arakawa S, Hata Y, Yonemoto K, Doi Y, et al.
- 385 Prevalence and systemic risk factors for retinal vein occlusion in a general
- 386 Japanese population: the Hisayama study. Invest Ophthalmol Vis Sci. 2010;51:
- 387 3205-3209. doi: [10.1167/iov.09-4453](#), PubMed PMID: [20071683](#).
- 388 15. Kolar P. Risk factors for central and branch retinal vein occlusion: a meta-
- 389 analysis of published clinical data. J Ophthalmol. 2014;2014. Epub: 724780:
- 390 724780. doi: [10.1155/2014/724780](#), PubMed PMID: [25009743](#), PubMed Central
- 391 PMCID: [PMC4070325](#).
- 392 16. Hamid S, Mirza SA, Shokh I. Branch retinal vein occlusion. J Ayub Med Coll
- 393 Abbottabad. 2008;20: 128-132. [Epub 2009/04/24]. PubMed PMID: [19385476](#).
- 394 17. Bradshaw SE, Gala S, Nanavaty M, Shah A, Mwamburi M, Kefalas P.
- 395 Systematic literature review of treatments for management of complications of
- 396 ischemic central retinal vein occlusion. BMC Ophthalmol. 2016;16: 104. Epub:
- 397 104. doi: [10.1186/s12886-016-0282-5](#), PubMed PMID: [27401800](#), PubMed
- 398 Central PMCID: [PMC4940864](#).
- 399 18. Falavarjani KG, Nguyen QD. Adverse events and complications associated
- 400 with intravitreal injection of anti-VEGF agents: a review of literature. Eye (Lond).

- 2013;27: 787-794. Epub: 787–794. doi: [10.1038/eye.2013.107](https://doi.org/10.1038/eye.2013.107), PubMed PMID: [23722722](https://pubmed.ncbi.nlm.nih.gov/23722722/), PubMed Central PMCID: [PMC3709385](https://pubmed.ncbi.nlm.nih.gov/PMC3709385/).
19. Porta M, Striglia E. Intravitreal anti-VEGF agents and cardiovascular risk. Intern Emerg Med. 2020;15: 199-210. Epub: 199–210. doi: [10.1007/s11739-019-02253-7](https://doi.org/10.1007/s11739-019-02253-7), PubMed PMID: [31848994](https://pubmed.ncbi.nlm.nih.gov/31848994/).
20. Matsuyama K, Ogata N, Matsuoka M, Wada M, Takahashi K, Nishimura T. Plasma levels of vascular endothelial growth factor and pigment epithelium-derived factor before and after intravitreal injection of bevacizumab. Br J Ophthalmol. 2010;94(9):1215-8. Epub: 20100610. doi: [10.1136/bjo.2008.156810](https://doi.org/10.1136/bjo.2008.156810), PubMed PMID: [20538658](https://pubmed.ncbi.nlm.nih.gov/20538658/).
21. Cortinovis A, Crippa A, Crippa M. Factor VIII/Ag (von Willebrand) and protein C. Erythrocyte deformability and aggregability. The risk parameters of retinal vein occlusion. Minerva Med. 1994;85: 211-219. [Epub 1994/05/01]. PubMed PMID: [8028749](https://pubmed.ncbi.nlm.nih.gov/8028749/).
22. Lip PL, Blann AD, Jones AF, Lip GY. Abnormalities in haemorheological factors and lipoprotein (a) in retinal vascular occlusion: implications for increased vascular risk. Eye (Lond). 1998;12: 245-251. doi: [10.1038/eye.1998.58](https://doi.org/10.1038/eye.1998.58), PubMed PMID: [9683948](https://pubmed.ncbi.nlm.nih.gov/9683948/).

- 419 23. Boyd S, Owens D, Gin T, Bunce K, Sherafat H, Perry D, et al. Plasma
420 homocysteine, methylene tetrahydrofolate reductase C677T and factor II
421 G20210A polymorphisms, factor VIII, and VWF in central retinal vein occlusion.
422 Br J Ophthalmol. 2001;85: 1313-1315. doi: [10.1136/bjo.85.11.1313](https://doi.org/10.1136/bjo.85.11.1313), PubMed
423 PMID: [11673296](https://pubmed.ncbi.nlm.nih.gov/11673296/), PubMed Central PMCID: [PMC1723784](https://pubmed.ncbi.nlm.nih.gov/PMC1723784/).
- 424 24. Matsumoto M, Kawaguchi S, Ishizashi H, Yagi H, Iida J, Sakaki T, et al.
425 Platelets treated with ticlopidine are less reactive to unusually large von
426 Willebrand factor multimers than are those treated with aspirin under high shear
427 stress. Pathophysiol Haemost Thromb. 2005;34: 35-40. doi:
428 [10.1159/000088546](https://doi.org/10.1159/000088546), PubMed PMID: [16293984](https://pubmed.ncbi.nlm.nih.gov/16293984/).
- 429 25. Kato S, Matsumoto M, Matsuyama T, Isonishi A, Hiura H, Fujimura Y. Novel
430 monoclonal antibody-based enzyme immunoassay for determining plasma
431 levels of ADAMTS13 activity. Transfusion. 2006;46: 1444-1452. doi:
432 [10.1111/j.1537-2995.2006.00914.x](https://doi.org/10.1111/j.1537-2995.2006.00914.x), PubMed PMID: [16934083](https://pubmed.ncbi.nlm.nih.gov/16934083/).
- 433 26. Kanda Y. Investigation of the freely available easy-to-use software 'EZ' for
434 medical statistics. Bone Marrow Transplant. 2013;48: 452-458. doi:
435 [10.1038/bmt.2012.244](https://doi.org/10.1038/bmt.2012.244), PubMed PMID: [23208313](https://pubmed.ncbi.nlm.nih.gov/23208313/), PubMed Central PMCID:
436 [PMC3590441](https://pubmed.ncbi.nlm.nih.gov/PMC3590441/).

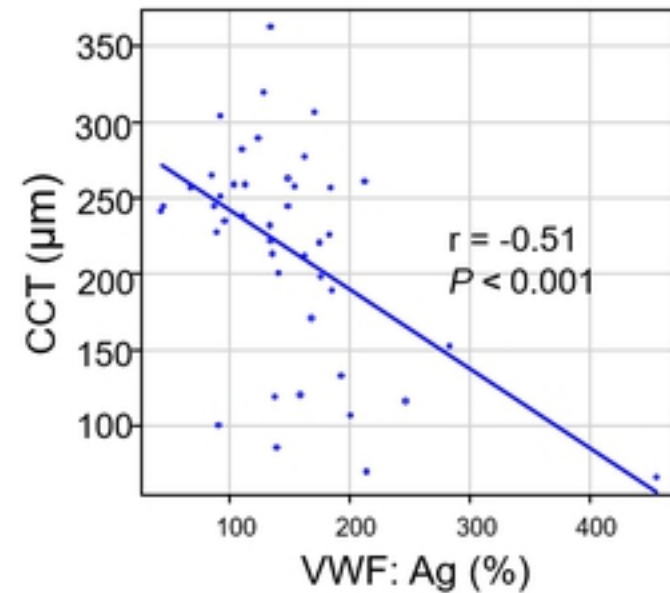
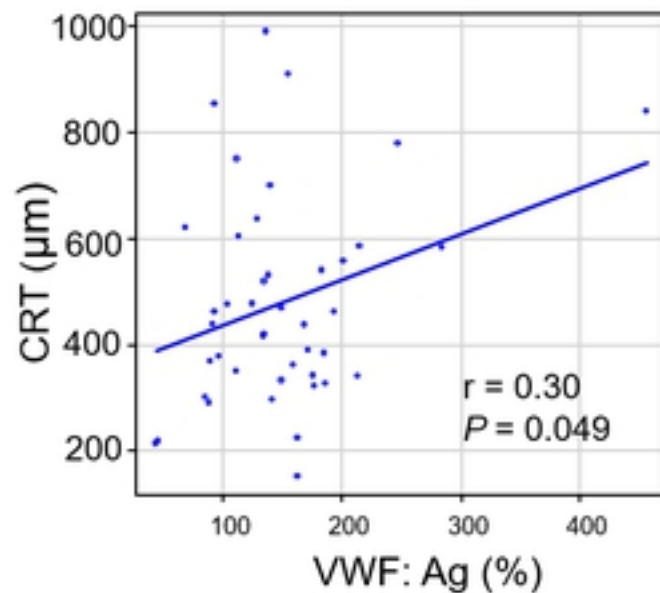
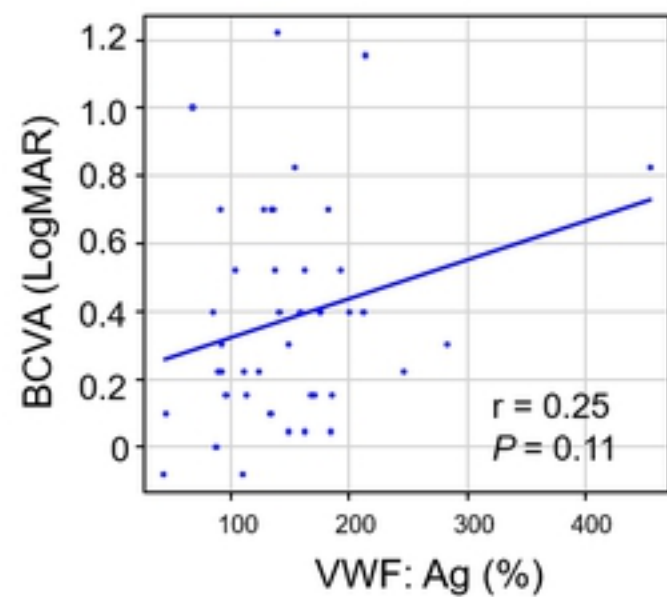
- 437 27. Gallinaro L, Cattini MG, Sztukowska M, Padrini R, Sartorello F, Pontara E,
438 et al. A shorter von Willebrand factor survival in O blood group subjects explains
439 how ABO determinants influence plasma von Willebrand factor. Blood.
440 2008;111: 3540-3545. doi: [10.1182/blood-2007-11-122945](https://doi.org/10.1182/blood-2007-11-122945), PubMed PMID:
441 [18245665](https://pubmed.ncbi.nlm.nih.gov/18245665/).
- 442 28. Alavi P, Rathod AM, Jahroudi N. Age-associated increase in
443 thrombogenicity and its correlation with von Willebrand factor. J Clin Med.
444 2021;10. Epub: 20210916. doi: [10.3390/jcm10184190](https://doi.org/10.3390/jcm10184190), PubMed PMID:
445 [34575297](https://pubmed.ncbi.nlm.nih.gov/34575297/), PubMed Central PMCID: [PMC8472522](https://pubmed.ncbi.nlm.nih.gov/PMC8472522/).
- 446 29. Biguzzi E, Castelli F, Lijfering WM, Cannegieter SC, Eikenboom J,
447 Rosendaal FR, et al. Rise of levels of von Willebrand factor and factor VIII with
448 age: role of genetic and acquired risk factors. Thromb Res. 2021;197: 172-178.
449 Epub: 172–178. doi: [10.1016/j.thromres.2020.11.016](https://doi.org/10.1016/j.thromres.2020.11.016), PubMed PMID:
450 [33221577](https://pubmed.ncbi.nlm.nih.gov/33221577/).
- 451 30. Hawkins WR. Anatomy of arteriovenous crossings in branch retinal vein
452 occlusion. Am J Ophthalmol. 1990;110: 97-98. doi: [10.1016/s0002-](https://doi.org/10.1016/s0002-9394(14)76953-3)
453 [9394\(14\)76953-3](https://doi.org/10.1016/s0002-9394(14)76953-3), PubMed PMID: [2368833](https://pubmed.ncbi.nlm.nih.gov/2368833/).
- 454 31. Frangieh GT, Green WR, Barraquer-Somers E, Finkelstein D.

- 455 Histopathologic study of nine branch retinal vein occlusions. Arch Ophthalmol.
456 1982;100: 1132-1140. doi: [10.1001/archopht.1982.01030040110020](https://doi.org/10.1001/archopht.1982.01030040110020), PubMed
457 PMID: [6178389](https://pubmed.ncbi.nlm.nih.gov/6178389/).
- 458 32. Lyu M, Lee Y, Kim BS, Kim HJ, Hong R, Shin YU, et al. Clinical significance
459 of subclinical atherosclerosis in retinal vein occlusion. Sci Rep.: 2021:
460 11(1):11905. Epub: 20210607. doi: [10.1038/s41598-021-91401-1](https://doi.org/10.1038/s41598-021-91401-1), PubMed
461 PMID: [34099806](https://pubmed.ncbi.nlm.nih.gov/34099806/), PubMed Central PMCID: [PMC8184809](https://pubmed.ncbi.nlm.nih.gov/PMC8184809/).
- 462 33. Gifford FJ, Moroni F, Farrah TE, Hetherington K, MacGillivray TJ, Hayes
463 PC, et al. The eye as a non-invasive window to the microcirculation in liver
464 cirrhosis: A prospective pilot study. J Clin Med. 2020;9. Epub: 20201017. doi:
465 [10.3390/jcm9103332](https://doi.org/10.3390/jcm9103332), PubMed PMID: [33080821](https://pubmed.ncbi.nlm.nih.gov/33080821/), PubMed Central PMCID:
466 [PMC7603064](https://pubmed.ncbi.nlm.nih.gov/PMC7603064/).
- 467 34. Kim KH, Lee DH, Lee JJ, Park SW, Byon IS, Lee JE. Regional choroidal
468 thickness changes in branch retinal vein occlusion with macular edema.
469 Ophthalmologica. 2015;234: 109-118. Epub: 109–118. doi: [10.1159/000437276](https://doi.org/10.1159/000437276),
470 PubMed PMID: [26305536](https://pubmed.ncbi.nlm.nih.gov/26305536/).
- 471 35. Sakanishi Y, Morita S, Mashimo K, Tamaki K, Ebihara N. Subfoveal
472 choroidal thickness and treatment outcomes of intravitreal Aflibercept for branch

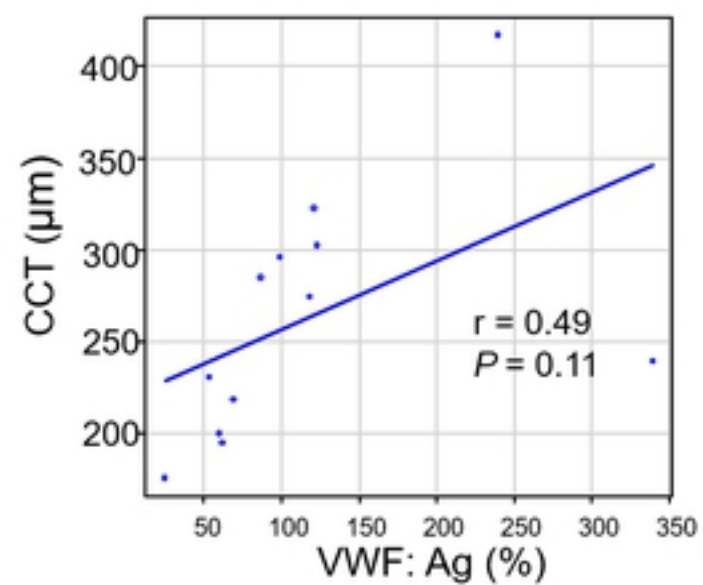
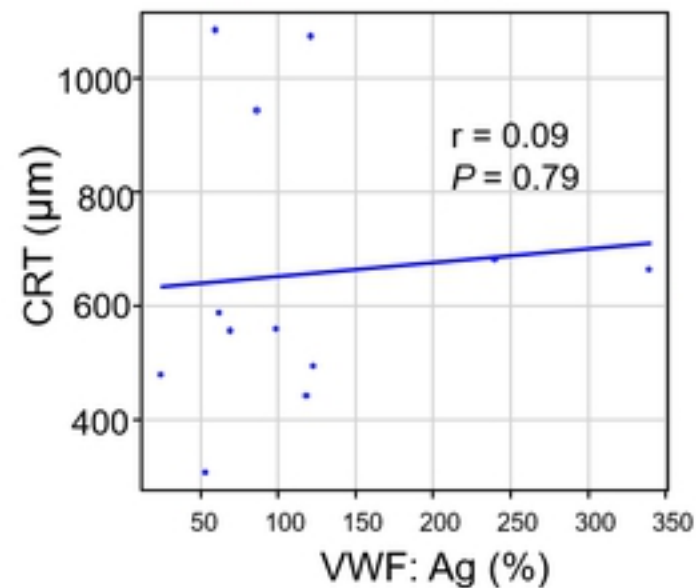
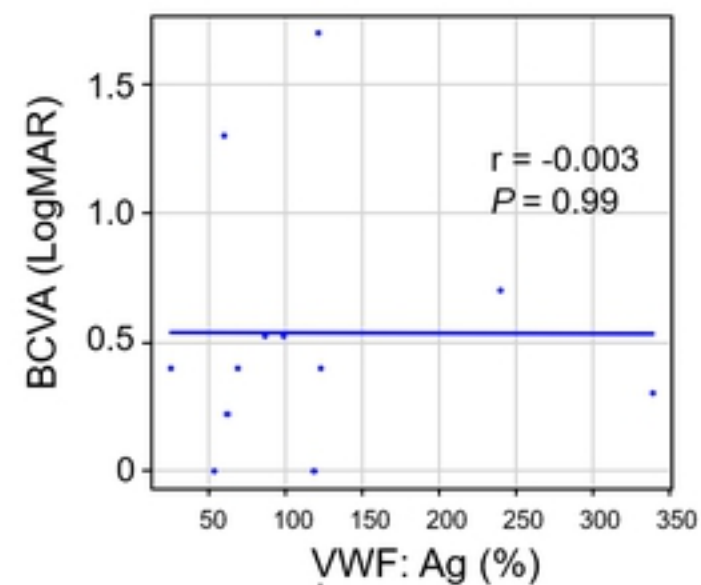
- 473 retinal vein occlusion. Life (Basel). 2021;11. Epub: 20210617. doi:
- 474 [10.3390/life11060572](https://doi.org/10.3390/life11060572), PubMed PMID: [34204557](https://pubmed.ncbi.nlm.nih.gov/34204557/), PubMed Central PMCID:
- 475 [PMC8235093](https://pubmed.ncbi.nlm.nih.gov/PMC8235093/).
- 476 36. Ishihara J, Ishihara A, Starke RD, Peghaire CR, Smith KE, McKinnon TAJ,
- 477 et al. The heparin binding domain of von Willebrand factor binds to growth
- 478 factors and promotes angiogenesis in wound healing. Blood. 2019;133: 2559-
- 479 2569. Epub: 2559–2569. doi: [10.1182/blood.2019000510](https://doi.org/10.1182/blood.2019000510), PubMed PMID:
- 480 [30975637](https://pubmed.ncbi.nlm.nih.gov/30975637/), PubMed Central PMCID: [PMC6566593](https://pubmed.ncbi.nlm.nih.gov/PMC6566593/).
- 481 37. Rondaij MG, Bierings R, Kragt A, van Mourik JA, Voorberg J. Dynamics and
- 482 plasticity of Weibel-Palade bodies in endothelial cells. Arterioscler Thromb Vasc
- 483 Biol. 2006;26: 1002-1007. doi: [10.1161/01.ATV.0000209501.56852.6c](https://doi.org/10.1161/01.ATV.0000209501.56852.6c), PubMed
- 484 PMID: [16469951](https://pubmed.ncbi.nlm.nih.gov/16469951/).
- 485 38. Randi AM. Endothelial dysfunction in von Willebrand disease: angiogenesis
- 486 and angiodysplasia. Thromb Res. 2016;141;Suppl 2: S55-S58. doi:
- 487 [10.1016/S0049-3848\(16\)30366-8](https://doi.org/10.1016/S0049-3848(16)30366-8), PubMed PMID: [27207426](https://pubmed.ncbi.nlm.nih.gov/27207426/).
- 488 39. Mojzisch A, Brehm MA. The manifold cellular functions of von Willebrand
- 489 factor. Cells. 2021;10. Epub: 20210908. doi: [10.3390/cells10092351](https://doi.org/10.3390/cells10092351), PubMed
- 490 PMID: [34572000](https://pubmed.ncbi.nlm.nih.gov/34572000/), PubMed Central PMCID: [PMC8466076](https://pubmed.ncbi.nlm.nih.gov/PMC8466076/).

491 40. Pace A, Mandoj C, Antenucci A, Villani V, Sperduti I, Casini B, et al. A
 492 predictive value of von Willebrand factor for early response to bevacizumab
 493 therapy in recurrent glioma. J Neurooncol. 2018;138: 527-535. doi:
 494 [10.1007/s11060-018-2820-x](https://doi.org/10.1007/s11060-018-2820-x), PubMed PMID: [29594657](https://pubmed.ncbi.nlm.nih.gov/29594657/).

BRVO

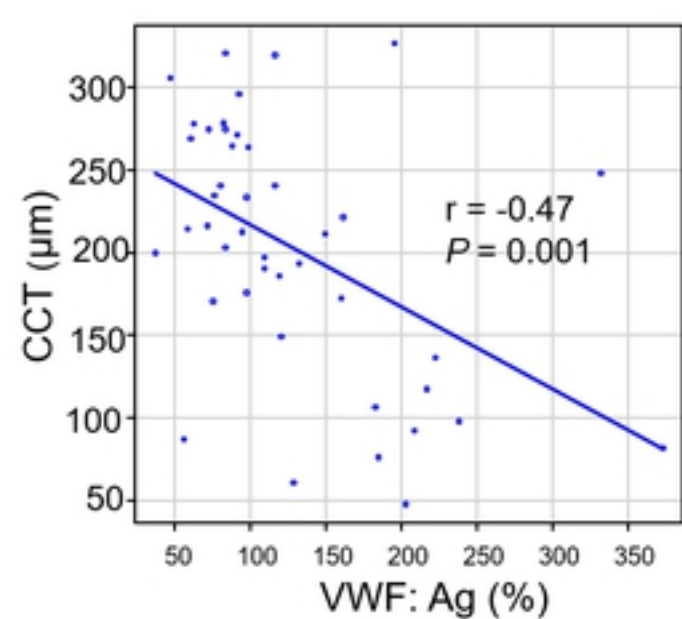
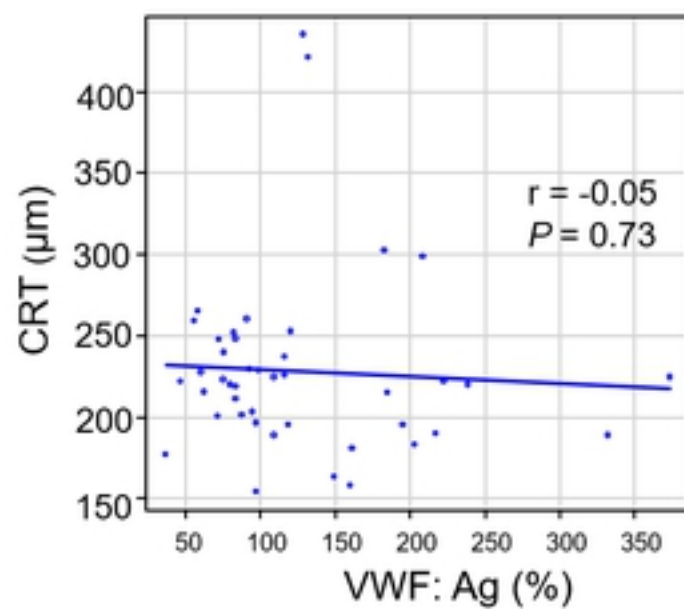
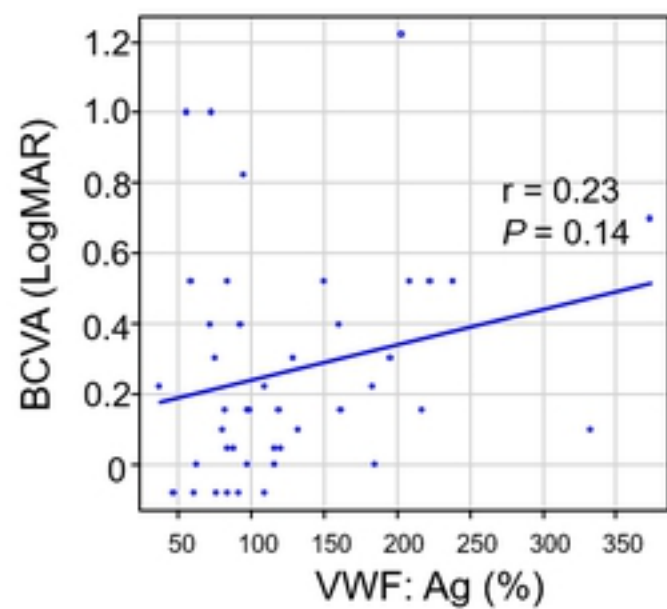


CRVO

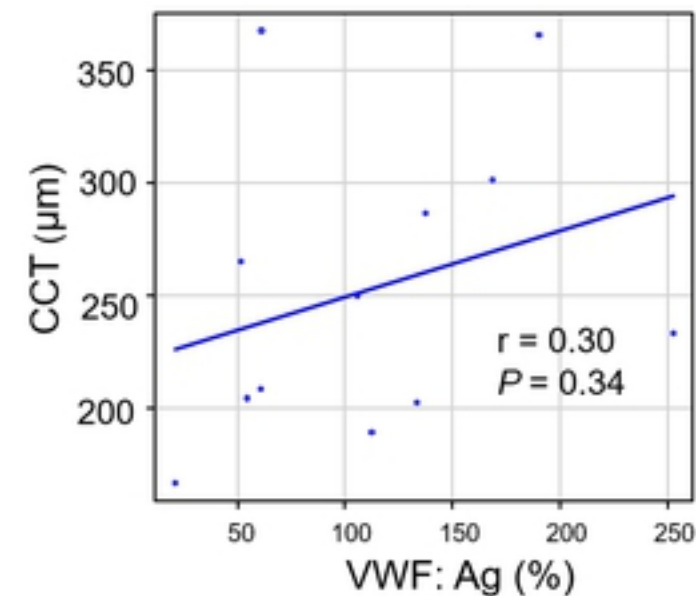
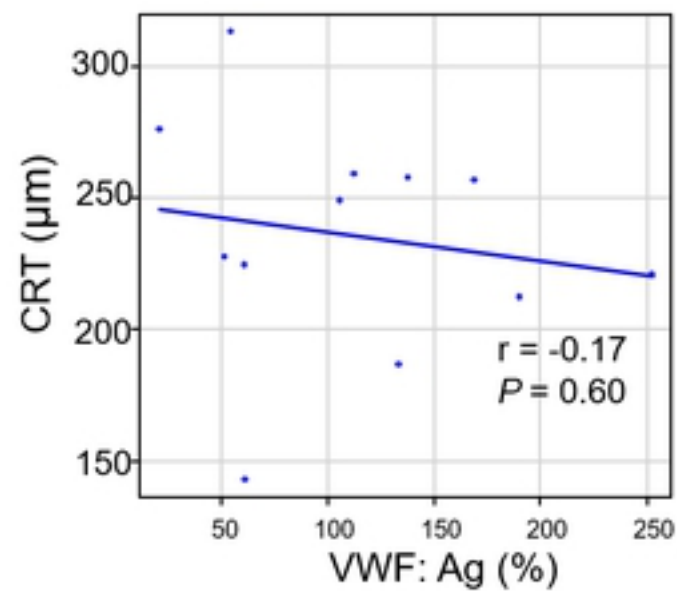
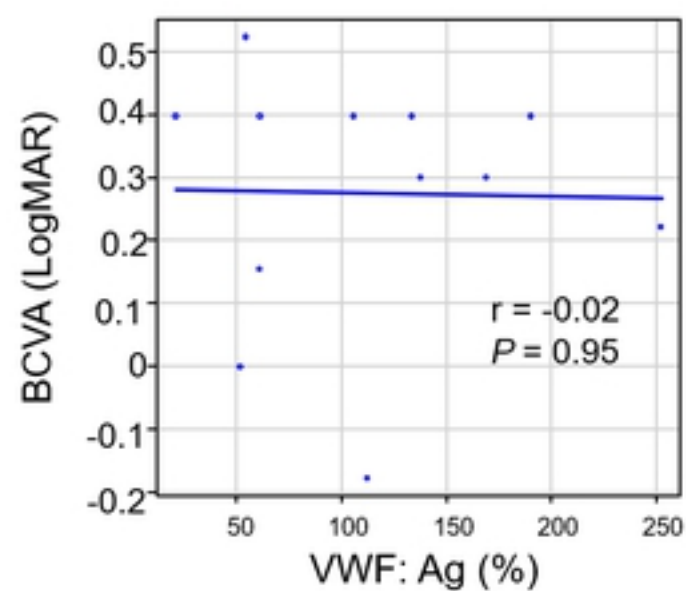


Figure

BRVO

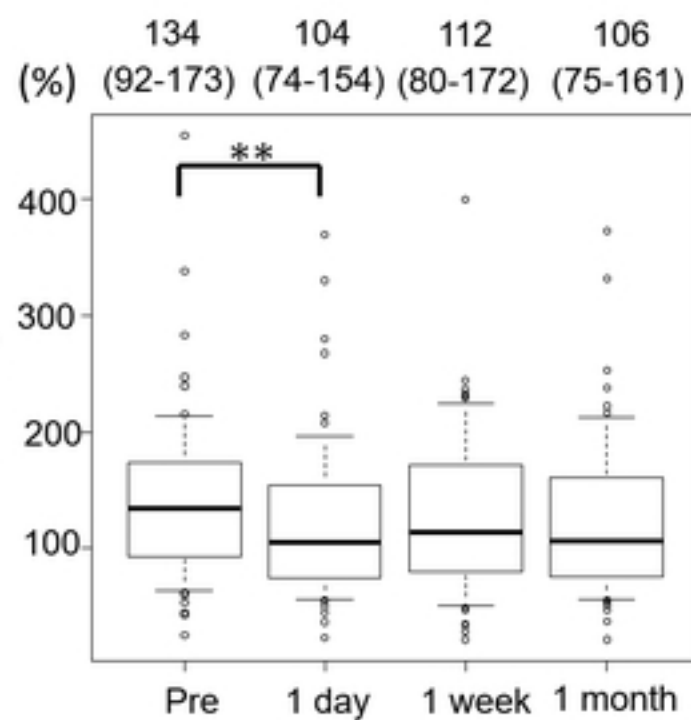


CRVO

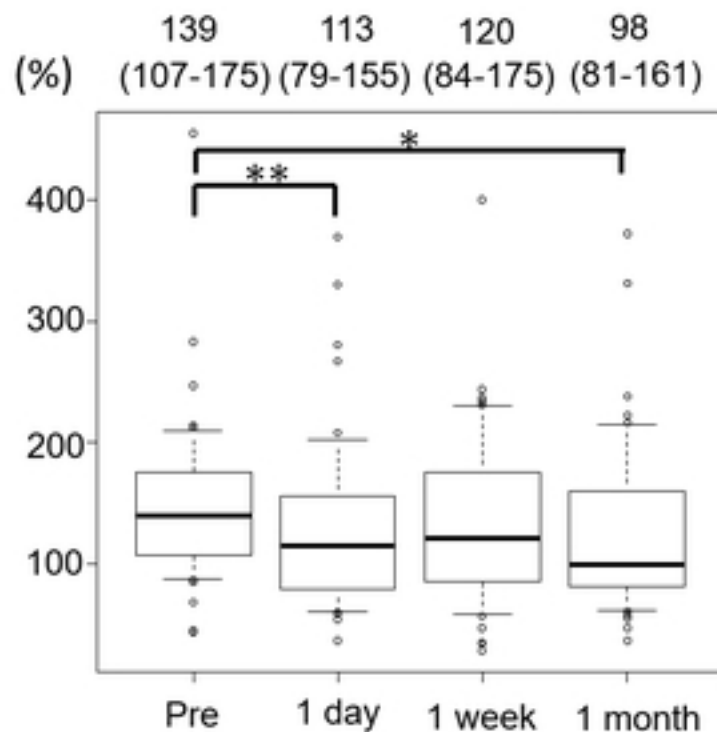


Figure

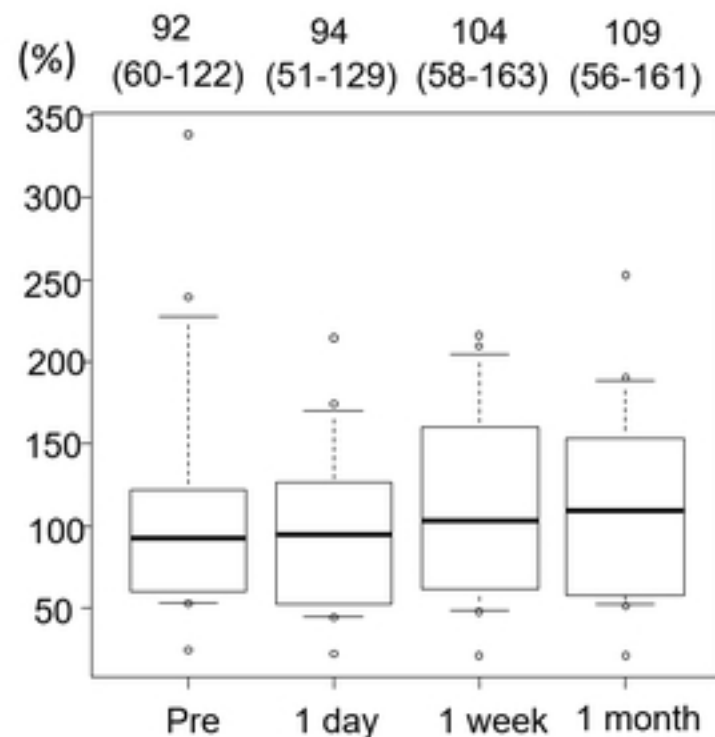
Total RVO



BRVO



CRVO



Figure