

1 **Bowel Colonization by Non-Commensal Fungi in**
2 **Neonatal Obstructive Cholangitis and Biliary Atresia**

3
4 Song-Wei Huang^{1,†}, M.Sc., Chia-Ray Lin^{2,†}, Ph.D., Ya-Hui Chang¹, M.Sc., Yen-Hsuan Ni²,
5 M.D., Ph.D., Huey-Ling Chen^{2,*}, M.D., Ph.D., Hong-Hsing Liu^{1,3,*}, M.D., Ph.D.

6
7 ¹ Institute of Molecular and Genomic Medicine, National Health Research Institutes,
8 Zhunan Town, Miaoli County 35053, Taiwan

9 ² Pediatrics Department, National Taiwan University Children's Hospital, Taipei,
10 100225, Taiwan

11 ³ Pediatrics, En Chu Kong Hospital, Sanxia District, New Taipei City 237414, Taiwan

12 †Equal contribution as first author

13 *Equal contribution as senior author

14 Correspondence: hhliu@nhri.edu.tw; honghsing.liu@gmail.com

15
16

17 **Abstract**

18 Up to two-thirds of biliary atresia (BA) patients need liver transplantation after the
 19 standard Kasai portoenterostomy treatment. Unrelenting cholangitis often
 20 precedes the full-blown presentation of BA. Using ribosomal 18S sequencing, here
 21 we report bowel colonization by non-commensal *Aspergillus* fungi in one case of
 22 neonatal obstructive cholangitis. Continuous oral fluconazole treatment resolved
 23 obstructive cholangitis completely. Colonization by non-commensal *Aspergillus* and
 24 *Cerrena* were additionally identified in 2 BA cases. In brief, bowel colonization by
 25 non-commensal fungi could be a treatable cause of neonatal obstructive cholangitis
 26 and potentially BA at an early stage.
 27

28 Introduction

29 Inflammation of bile ducts or cholangitis in newborns is uncommon. However, it
30 can be a devastating prelude to biliary atresia (BA), the pathologic condition of
31 obliterated bile outlets. BA patients have characteristically low fecal bile pigments
32 at disease onset, and eventually develop clay-colored stools. Kasai
33 portoenterostomy, which surgically rechannels between interhepatic bile ducts and
34 intestine, is currently the standard first-line treatment for BA[1]. However, up to
35 two-thirds of patients will still require liver transplantation[2] due to unrelenting
36 bile-duct obstruction and subsequent liver cirrhosis. The underlying cause for BA
37 has remained unknown.

38 Here we describe a case of neonatal obstructive cholangitis associated with
39 colonization by non-commensal *Aspergillus* fungi. Oral anti-fungal fluconazole
40 successfully resolved cholangitis and normalized bilirubin levels. Drawing from
41 these findings, we suspected that BA could share a similar pathogenic mechanism.
42 Indeed, feces of two BA patients showed colonization by non-commensal *Cerrena*
43 and *Aspergillus* fungi. Healthy controls showed colonization only by commensal
44 fungi *Candida sp.* and *Malassezia furfur*.

45

46 Methods

47 Human subjects

48 Use of clinical samples and report of clinical data have been approved by the
49 Institutional Review Boards of National Taiwan University Children's Hospital and En
50 Chu Kong Hospital.

51

52 Fecal DNA extraction

53 Fecal samples from the index case were collected and stored at -80°C before use.
54 DNA was extracted from 50-200mg stool using ZymoBIOMICS DNA Miniprep Kit
55 (Zymo, D4300) according to manufacturer's protocols. Fecal DNA for BA cases and
56 controls were extracted with QIAamp PowerFecal Pro DNA Kits.

57

58 18S PCR and Sanger sequencing

59 All polymerase chain reactions (PCR) were performed with KAPA HiFi HotStart
60 ReadyMix PCR Kit (Roche, KK2602). For 18S V1-V8 PCR, DNA samples were run with
61 primers 18S-F-bc1005C-P5 (5'-AATGATACGGCGACCACCGAGATCTACACGTGAG
62 CTGAGAGCGCACCATGTCATGTCTAAGTWTAA -3') and 18S-R-bc1033C-P7 (5'- CAAGCAG
63 AAGACGGCATACGAGATTCTCTGACGCTGCTCTAICCATTCATCGGTAIT -3'). PCR was
64 performed on MiniAmp plus Thermal Cycler (Thermo Fisher Scientific, A37835) with
65 the following conditions: 95°C 3m, 5 cycles of 98°C 30s + 54°C 30s + 72°C 1m30s, 5

66 cycles of 98°C 30s + 51°C 30s + 72°C 1m30s, 30 cycles of 98°C 30s + 48°C 30s + 72°C
67 1m30s, and a final extension of 72°C 3m30s. Yeast cDNA and ddH₂O were used as
68 positive and negative controls, respectively. For semi-nested 18S V7-V8 PCR, the
69 first V1-V8 PCR was performed as above except with the last 30 cycles before final
70 extension reduced to 20 cycles. 1µl of V1-V8 PCR products was used to template
71 each semi-nested V7-V8 PCR with primers 18S-F-nu-SSU-1333-5' (5'-
72 CGWTAACGAACGAGACCT-3') and 18S-R-bc1033C-P7. Thermocycling conditions
73 were 95°C 3m, 5 cycles of 98°C 30s + 54°C 30s + 72°C 1m, 5 cycles of 98°C 30s + 51°C
74 30s + 72°C 1m, 20 cycles of 98°C 30s + 48°C 30s + 72°C 1m, and a final extension of
75 72°C 3m30s. Semi-nested V7-V8 amplicons were purified with MinElute PCR
76 Purification Kit (QIAGEN, #28006) before Sanger sequencing.

78 **16S PCR**

79 All 16S PCR were performed with KAPA HiFi HotStart ReadyMix PCR Kit (Roche,
80 KK2602). V1-V9 regions were amplified with primers 16S-F-bc1005-P5
81 (5'-AATGATACGGCGACCACCGAGATCTACACCACTCGACTCTCGCTAGRGTTYGATYMTGG
82 CTCAG-3') and 16S-R-bc1033-P7
83 (5'-CAAGCAGAAGACGGCATACGAGATAGAGACTGCGACGAGARGYTACCTTGTTACGACTT-
84 3') using the following thermocycling conditions: 95 °C 3m, 27 cycles of 95°C 30s +
85 57°C 30s + 72°C 1m, and a final extension of 72°C 3m. *E. coli* DH5α DNA and ddH₂O
86 were used as positive and negative controls, respectively.

88 **Bioinformatic analyses**

89 Sequences from Sanger sequencing were analyzed with SnapGene software
90 (www.snapgene.com). Nucleotide BLAST[3] was performed using the National
91 Center for Biotechnology Information server.

93 **Results**

94 **Fungal cholangitis in a newborn**

95 A newborn male was delivered emergently by Caesarean section (C/S) due to fetal
96 distress at 39 weeks of gestation. Cardiac arrest and thick meconium stains were
97 noted. After successful resuscitation, the patient was sent to Neonatal Intensive
98 Care Unit (NICU) for further management. Severe hypoglycemia (< 2 mg/dL) was
99 detected at admission. Continuous supply of 10% glucose *via* peripheral lines
100 barely maintained blood glucose levels. Without central lines, early oral feeding
101 with 50% concentrated glucose water was begun one day after birth (D1) for one
102 week. Insulin and cortisol responses were normal as evaluated on D3, and there
103 was no evidence of inborn errors of metabolism. Vital signs were stable and no

neural sequelae were found. However, ileus with distended abdomen later complicated the course in spite of full antibiotic coverage. Severe thrombocytopenia with normal counts of white blood cells was noted (D8, D11, Figure 1A). Fungal infection was suspected, so intravenous (i.v.) fluconazole was administered from D11. Dramatic clinical improvement followed, and fluconazole was discontinued on D19. However, severe leukocytosis of 20,400/ μ L on D15 and 28,300/ μ L on D19 required another empirical course of i.v. antibiotics (D19-D26), but in vain (D27, Figure 1A).

During this period direct-type hyperbilirubinemia with high gamma-glutamyltransferase (γ -GT) values (D27, Figure 1B) was preceded by clotrimazole-responsive perianal dermatophytosis (D23, Figure 1C) and light-colored stool (D26, Figure 1C). Under suspicion of fungal cholangitis, amphotericin B was administered from D27 to D29 (Figure 1B). Without improvement on bilirubin levels, anti-fungal medication was shifted to oral fluconazole from D30 (Figure 1B). Interestingly, stool color turned to yellow on the next day (D31, Figure 1C), with presentation improving in subsequent days (D38, Figure 1C). At the same time, hyperbilirubinemia subsided gradually (Figure 1B). Abdominal echo showed a well-distended gall bladder and no bile duct obstructions (D40, Figure 1C). The patient was discharged on D41, and kept on oral fluconazole. Follow-up blood cell counts, bilirubin levels, and γ -GT values were normal (Figures 1A and 1B). Daily oral fluconazole was tapered to three times weekly for two weeks, twice weekly for two weeks, and finally once weekly for one month. The patient developed and grew normally as far as the last clinical check at five months old. Fungal cultures of blood or stool collected during the patient's stay in the hospital all yielded negative results.

Cholangitis associated with *Aspergillus* sp.

We used fungal-ribosomal 18S PCR[4-6] to characterize suspected fungal infection from fecal DNA. Bacterial 16S V1-V9 PCR[5] served as internal control (Figure 2A). One 18S V1-V8 band was clearly amplified from the D28 fecal sample (Figure 2A), though amphotericin B was given i.v. from D27 to D29 (Figure 1B). The V1-V8 band disappeared (D31, D38, Figure 2A) after oral administration of fluconazole from D30 (Figure 1B). Products from 18S V1-V8 PCR were used to amplify the V7-V8 region for taxonomical classification through semi-nested PCR (red arrow, Figure 2A). Sequence results identified *Aspergillus* sp. by nucleotide BLAST[3] against the nr/nt database[7] (Figure 2B and Table 1).

Non-commensal fungal colonization in biliary atresia

Aspergillus sp. is not a usual fungal commensal of the gastrointestinal tract[8]. We

142 suspect that BA, a disease also characterized by bile-duct inflammation, could be
143 related to colonization by unusual fungi in newborn bowels. We subjected fecal
144 DNA from five cases of BA and four healthy controls to 18S V1-V8 and nested V7-V8
145 PCR (Figure 2C). Four samples (BA-1, -3, -5 and control-3) yield positive results (red
146 arrow, Figure 2C). Sequences from BA-1 are mapped to *Cerrena sp.* (Figure 2D and
147 Table 1). *Aspergillus sp.* is also identified in BA-5 (Table 1). BA-3 and control-3 are
148 related to *Candida* (Table 1). Of four additional control samples, three yield
149 sequences from *Candida* and one has sequences from *Malassezia* (Table 1).
150 Non-commensal fungi are not identified in any controls. The Fisher exact test
151 statistic is 0.0476 (<0.05) between controls and patients who had molecular evidence
152 of fungal colonization.

153

154 **Distinct *Aspergillus sp.* between patients**

155 Both the cholangitis case and BA-5 are associated with bowel colonization by
156 *Aspergillus sp.* (Table 1). We align 18S V7-V8 sequences to compare identities.
157 We find that at least two loci have distinct T vs. C nucleotide polymorphisms (red
158 arrow, Figure 2E). This result suggests that the two patients' bowels were colonized
159 by different *Aspergillus*.

160

161 **Discussion**

162 There have been no reports of neonatal fungal cholangitis in the literature. Before
163 the onset of hyperbilirubinemia, the index case experienced a course of
164 gastroenteritis which responded to fluconazole but not antibiotics. Prior week-long
165 ingestion of concentrated glucose water *per os* could have contributed to fungal
166 overgrowth. Notably, the patient suffered fetal distress before emergent C/S and
167 had a glucose level undetectable at NICU admission. Congenital fungal infection
168 could not be ruled out.

169 Immune mechanisms for occurrence of cholangitis are unclear. At the
170 gastroenteritis stage platelet counts were very low, but at the cholangitis stage
171 platelet counts were normal (Figure 1A). Underlying pathogenesis may differ.
172 Fungi could cause immune overreaction at the cholangitis stage but direct invasion
173 might dominate the gastroenteritis stage. These hypotheses might be tested once
174 culture conditions for implicated fungi, especially *Aspergillus sp.* (Figure 2B), are
175 established.

176 Drawing on these findings, we suspected BA could share a fungal pathogenic
177 mechanism. Indeed, we found colonization by non-commensal fungi in two BA
178 patients, but not in controls. 18S analyses revealed *Cerrena sp.* in BA-1 and
179 *Aspergillus sp.* in BA-5 (Table 1). Neither *Cerrena sp.* nor *Aspergillus sp.* are

gastrointestinal commensals, though both are identifiable from human respiratory tracts[9]. These fungi might take advantage of compromised immunity in newborns to overgrow and overstimulate immature immune systems. One report describes a complicating *Aspergillus sp.* infection following Kasai portoenterostomy[10], supporting our observation of fungal overgrowth in BA patients. Though two BA cases lacked identifiable fungi, their immune systems could still have overreacted to low amounts of fungi in bowels. The index cholangitis case is an example. Although PCR did not detect fungi after fluconazole administration (D31, Figure 2A), white blood cell counts remained high for more than 10 days (Figure 1A). It is possible that trace fungal stimulants in bowels could have exponentially pathogenic effects under some circumstances.

The index case with cholangitis was successfully treated with oral fluconazole. If overgrowth and overstimulation by non-commensal fungi accounts for at least part of BA pathogenesis, early anti-fungal treatment among BA patients should be considered. Using current standard surgical interventions, two-thirds of patients still eventually require liver transplantation[2]. If BA clinical course can be significantly altered, benefits of anti-fungal treatment would clearly outweigh the small associated hepatitis risk[11].

Acknowledgements

We thank Dr. Mei-Hwei Chang for professional discussion and significant support. Dr. Shiu-Feng Huang's inputs are greatly appreciated. We thank Chih-Wei Joshua Liu (MIT Physics of Living Systems) for English editing.

Author Contributions

S.W.H., C.J.L., and Y.H.C. conducted and optimized experiments. Y.H.N. and H.L.C. contributed samples and helped elaborate the study. H.H.L. initiated the project and proposed the hypothesis.

Competing Financial Interests

The authors declare no conflict of interests.

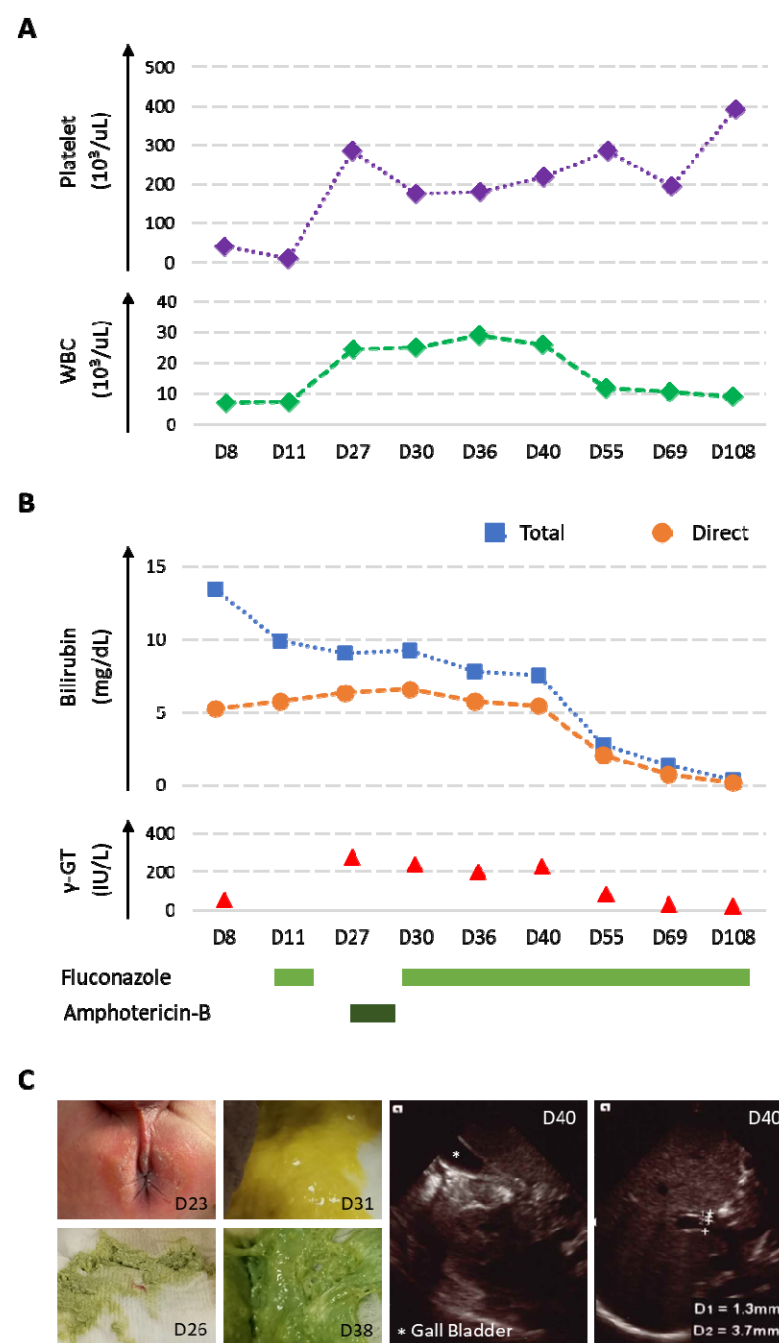
Table 1. Top two hits of nested 18S V7-V8 nucleotide BLAST.

Sample	Age(mo)	Diagnosis	Nested 18S V7-V8 BLAST hits*	Note
ECK-D28	0.9	Cholangitis	<i>Aspergillus sp.</i> (98.73%); <i>Aspergillus sp.</i> (98.73%)	Figure 2A
ECK-D31	1.0	Cholangitis	Not available	Figure 2A

ECK-D38	1.3	Cholangitis	Not available	Figure 2A
BA-1	1.7	Biliary Atresia	<i>Cerrena sp.</i> (98.74%); <i>Cerrena sp.</i> (98.74%)	Figure 2C
BA-2	1.1	Biliary Atresia	Not available	Figure 2C
BA-3	2.4	Biliary Atresia	Uncultured fungus (99.04%); <i>Candida parapsilosis</i> (99.04%)	Figure 2C
BA-4	3.9	Biliary Atresia	Not available	Figure 2C
BA-5	0.6	Biliary Atresia	<i>Aspergillus sp.</i> (98.12%); <i>Aspergillus sp.</i> (98.12%)	Figure 2C
Control-1	1.0	Normal	Not available	Figure 2C
Control-2	1.0	Normal	Not available	Figure 2C
Control-3	2.0	Normal	Uncultured fungus (98.40%); <i>Candida parapsilosis</i> (98.39%)	Figure 2C
Control-4	2.0	Normal	Not available	Figure 2C
Control-5	1.0	Normal	<i>Candida albicans</i> (98.06%); <i>Candida albicans</i> (98.06%)	Same baby
Control-6	2.0	Normal	<i>Candida albicans</i> (99.62%); <i>Candida albicans</i> (99.62%)	
Control-7	1.0	Normal	Uncultured fungus (99.60%); <i>Candida parapsilosis</i> (99.60%)	Same
Control-8	2.0	Normal	<i>Malassezia furfur</i> (100.00%); <i>Malassezia furfur</i> (100.00%)	baby

*First and second hits, respectively. Percent identities in parentheses.

217 **Figures**



218

219 **Figure 1.** Clinical presentation of the cholangitis case. A. Profiles of platelets and
 220 white blood cell counts are distinct between early gastroenteritis stage and late
 221 cholangitis stage. B. Blood bilirubin levels and γ-GT values decrease following
 222 fluconazole treatment. C. Perianal dermatophytosis is consistent with fungal
 223 colonization in stool. A series of stool phenotypes and abdominal ultrasonographs
 224 show resolution of cholangitis.

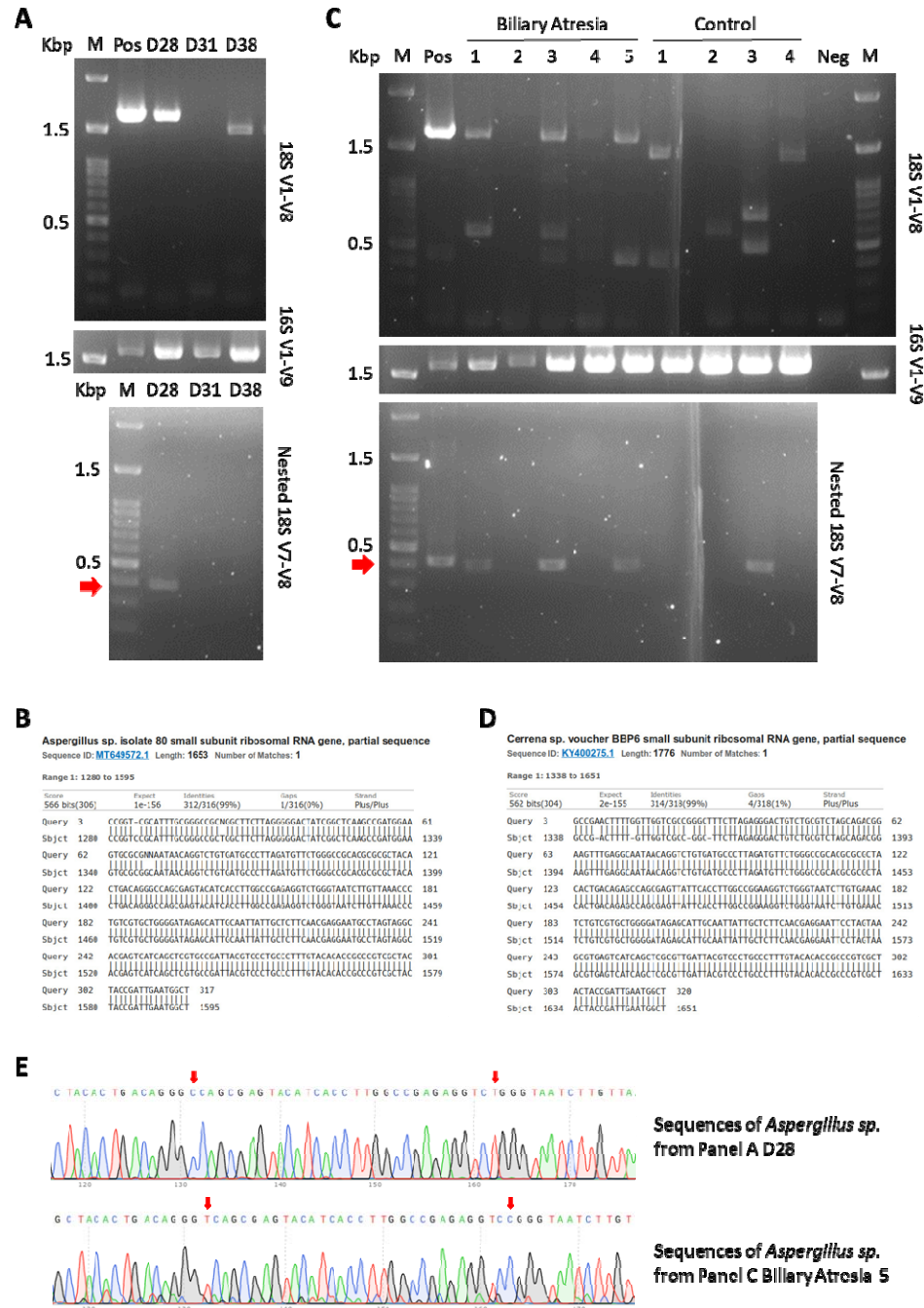


Figure 2. Molecular identification of fungal species with 18S ribosomal sequences. A. 18S V1-V8 and semi-nested V7-V8 (red arrow) PCRs from fecal DNA of the cholangitis case are shown. 16S V1-V9 PCR is used as internal control. B. *Aspergillus sp.* is identified in stool from the index case. C. 18S V1-V8 and semi-nested V7-V8 (red arrow) PCRs were performed against fecal DNA from BA patients and healthy controls. D. V7-V8 sequences of BA-1 match *Cerrena sp.* E. *Aspergillus sp.* are distinct between the cholangitis case and BA-5.

References

1. Kasai, M., *Treatment of biliary atresia with special reference to hepatic porto-enterostomy and its modifications*. Prog Pediatr Surg, 1974. **6**: p. 5-52.
2. Yoeli, D., et al., *Primary vs. salvage liver transplantation for biliary atresia: A retrospective cohort study*. J Pediatr Surg, 2022. **57**(10): p. 407-413.
3. Altschul, S.F., et al., *Basic local alignment search tool*. J Mol Biol, 1990. **215**(3): p. 403-10.
4. Banos, S., et al., *A comprehensive fungi-specific 18S rRNA gene sequence primer toolkit suited for diverse research issues and sequencing platforms*. BMC Microbiol, 2018. **18**(1): p. 190.
5. Olsen, G.J., et al., *Microbial ecology and evolution: a ribosomal RNA approach*. Annu Rev Microbiol, 1986. **40**: p. 337-65.
6. Smit, E., et al., *Analysis of fungal diversity in the wheat rhizosphere by sequencing of cloned PCR-amplified genes encoding 18S rRNA and temperature gradient gel electrophoresis*. Appl Environ Microbiol, 1999. **65**(6): p. 2614-21.
7. Sayers, E.W., et al., *Database resources of the national center for biotechnology information*. Nucleic Acids Res, 2022. **50**(D1): p. D20-D26.
8. Limon, J.J., J.H. Skalski, and D.M. Underhill, *Commensal Fungi in Health and Disease*. Cell Host Microbe, 2017. **22**(2): p. 156-165.
9. Dufresne, P.J., et al., *High frequency of pathogenic Aspergillus species among nonsporulating moulds from respiratory tract samples*. Med Mycol, 2017. **55**(2): p. 233-236.
10. Erdman, S.H., B.J. Barber, and L.L. Barton, *Aspergillus cholangitis: A late complication after Kasai portoenterostomy*. J Pediatr Surg, 2002. **37**(6): p. 923-5.
11. Hay, R.J., *Risk/benefit ratio of modern antifungal therapy: focus on hepatic reactions*. J Am Acad Dermatol, 1993. **29**(1): p. S50-4.