

# **Inflammatory Type Focal Cerebral Arteriopathy of the Posterior Circulation in Children: a comparative cohort study**

## **Author(s):**

Nedelina Slavova<sup>1,2,3\*</sup>, MD

Robin Münger<sup>4\*</sup>

Iciar Sanchez-Albisua<sup>4</sup>, MD

Maria Regényi<sup>4</sup>, MD

Gabriela Oesch<sup>4</sup>, MD

Joël Fluss<sup>5</sup>, MD

Annette Hackenberg<sup>6</sup>, MD

Sébastien Lebon<sup>7</sup>, MD

Oliver Maier<sup>8</sup>, MD

Alexandre Datta<sup>9</sup>, MD

Sandra Bigi<sup>10,11</sup>, MD

Sebastian Grunt<sup>4</sup>, MD, PhD

Maja Steinlin<sup>4</sup>, MD

1. Support Center for Advanced Neuroimaging (SCAN), Institute of Diagnostic and Interventional Neuroradiology, University Hospital, Inselspital, Bern, Switzerland.

2. Pediatric Radiology, University of Basel Children's Hospital (UKBB) and University of Basel, Switzerland

3. Department of Neurology, University Hospital Bern, University of Bern, Bern, Switzerland.
4. Division of Neuropaediatrics, Development and Rehabilitation, Department of Paediatrics, Inselspital, Bern University Hospital, University of Bern, Switzerland
5. Department of Pediatrics, Gynecology and Obstetrics, Pediatric Neurology Unit, University Hospitals of Geneva, Geneva, Switzerland.
6. Department of Pediatric Neurology, University Children's Hospital, Zürich, Switzerland.
7. Pediatric Neurology and Neurorehabilitation Unit, Lausanne University Hospital, Lausanne, Switzerland.
8. Department of Pediatrics, Division of Child Neurology, Children's Hospital, St Gallen, Switzerland
9. Department of Pediatric Neurology and Developmental Medicine, University of Basel Children's Hospital, Basel.
10. Division of Pediatric Neurology, Department of Pediatrics, Children's Hospital Lucerne, Lucerne, Switzerland
11. Institute of Social and Preventive Medicine, University of Bern, Bern, Switzerland.

### **Equal Author Contributions:**

Nedelina Slavova and Robin Münger contributed equally to this work.

### **Corresponding Author:**

Robin Münger

Division of Neuropediatrics, Development and Rehabilitation, Department of Pediatrics,  
Inselspital, Bern University Hospital, University of Bern

E-mail: [robin.muenger@insel.ch](mailto:robin.muenger@insel.ch)

Short Title: Posterior Focal Cerebral Arteriopathy

Total word count: 5998

# 1 **Abstract**

## 2 **Background**

3 Inflammatory type Focal Cerebral Arteriopathy (FCA-i) in the anterior circulation (AC) is  
4 well characterized and the FCA severity score (FCASS) reflects the severity of disease. We  
5 identified cases of FCA-i in the posterior circulation (PC) and adapted the FCASS to describe  
6 these cases.

## 7 **Methods**

8 Patients from the Swiss NeuroPaediatric Stroke Registry (SNPSR) with ischemic stroke in  
9 the PC and AC due to FCA-i and available neuroimaging were gathered. Comparison of data  
10 regarding Pediatric National Institutes of Health Stroke Scale (pedNIHSS) score and  
11 Pediatric Stroke Outcome Measure (PSOM) and FCASS was performed. We estimated  
12 infarct size by the modified pediatric Alberta Stroke Program Early Computed Tomography  
13 Score (pedASPECTS) in children with AC stroke and the adapted Bernese posterior  
14 diffusion-weighted imaging (DWI) score in the PC.

## 15 **Results**

16 Thirty-six children with a median age of 6.3 years ([IQR 2.8,8.6; range 0.9,15.6], 21 males,  
17 58.3%) with FCA-i were identified. The total incidence rate was 0.151/100 000/year (95%CI  
18 0.109–0.209). Seven had PC FCA-i and 5 had FCA-i in both circulations. Time to final  
19 FCASS was longer in the PC compared to AC, evolution of FCASS did not differ. Initial  
20 pedNIHSS was highest in children with FCA-i in the PC with a median of 8.0 (IQR 5.0-18.0),  
21 compared to 4.5 (IQR 2.0-8.0) in those with AC FCA-i and 6.0 (IQR 6.0-6.0) with  
22 involvement of both AC and PC. Different to the anterior cases PC infarct volume did not  
23 correlate with higher discharge, maximum or final FCASS scores (R 0.25, 0.35, 0.54).

## 24 Conclusion

25 The PC is affected in up to one third of cases of FCA-i. These cases should be included in  
 26 future investigations on FCA-i. Although it did not correlate with clinical outcome in our  
 27 cohort, the modified FCASS may well serve as a marker for the evolution of the arteriopathy  
 28 in posterior FCA-i.

## 29 Non-standard Abbreviations and Acronyms

AC	Anterior circulation
AICA	Anterior inferior cerebellar artery
AIS	Arterial ischemic Stroke
BA	Basilar artery
CI	Confidence intervall
CTA	Computed Tomography angiography
DNA	Desoxyribonucleic Acid
DWI	Diffusion-weighted imaging
FCA	Focal Cerebral Arteriopathy
FCA-d	Focal Cerebral Arteriopathy with intracranial arterial dissection
FCA-i	Inflammatory Focal Cerebral Arteriopathy
FCA-u	Focal Cerebral Arteriopathy undefined etiology
FCASS	Focal Cerebral Arteriopathy severity score
IQR	Interquartile range
MRA	Magnetic resonance angiography
PC	Posterior circulation
PCA	Posterior Cerebral artery
pedASPECTS	modified Pediatric Alberta Stroke Program Early Computed Tomography score
pedNIHSS	Paediatric National Institutes of Health Stroke Scale
PICA	Posterior inferior cerebellar artery
PSOM	Pediatric Stroke Outcome Measure
PVA	Post-varicella Arteriopathy
SCA	Superior cerebellar artery
SNPSR	Swiss NeuroPaediatric Stroke Registry
TCA	Transient Cerebral Arteriopathy
VA	Vertebral artery
VIPS	Vascular Effects of Infection in Pediatric Stroke
VWI	Vessel wall imaging
VZV	Varicella Zoster Virus

## Background

Focal cerebral arteriopathy of the inflammatory type (FCA-i) is an important risk factor for arterial ischemic stroke (AIS) in previously healthy children.<sup>1</sup> After the first description as transient cerebral arteriopathy in 1998<sup>2</sup>, FCA-I was defined in 2004<sup>2</sup> by a typical vascular imaging within 3 months after stroke showing unilateral focal or segmental stenosis or occlusion at a typical location, non-progressing on follow-up imaging 6 months post-stroke.<sup>3</sup> Typical locations include the distal part of the internal carotid artery and the initial segments of the anterior, middle and posterior cerebral arteries (A1, M1 and P1 segments). As a special variant, post-varicella arteriopathy (PVA) was defined as TCA with a history of acute varicella infection within the 12 months before AIS.<sup>4,5</sup> Since then, herpes simplex virus, enterovirus, Mycoplasma pneumoniae or Borrelia burgdorferi infections have been reported as risk factors for FCA-i and AIS.<sup>6-11</sup>

The term focal cerebral arteriopathy (FCA), which included unifocal or multifocal, unilateral or bilateral stenosis of variable etiologies (e.g. dissection or moyamoya disease and syndrome) was later defined, and TCA was seen as a subgroup of FCA<sup>12,13</sup>. In the large international Vascular Effects of Infection in Pediatric Stroke (VIPS) study, the definition of FCA was narrowed to unifocal and unilateral stenosis or irregularities of the AC. The VIPS study further subdivided FCA into three groups: intracranial arterial dissection (FCA-d), inflammation (FCA-i) or undefined etiology (FCA-u)<sup>1,14</sup>. FCA-i accounted for the majority of FCA in the VIPS study.<sup>1</sup> The evolution of FCA-i is characterized by a monophasic natural course, frequently showing early progression (over days to weeks), which reaches a plateau with non-progression by 6 months. The majority of individuals improve or remain stable, but complete resolution is seen in only a minority of cases.<sup>2,3</sup>

Based on the hypothesis of an inflammatory pathogenesis, corticosteroids are increasingly used to treat FCA-i.<sup>15</sup> However, there is still no clinical trial data to support this treatment.

56 The planning of forthcoming clinical trials in this field (Brechtbühl et. al., PASTA Trial,  
57 unpublished data, 2023) revealed the need for a quantitative measurement of FCA severity.  
58 This led to the development of the FCA Severity Score (FCASS) based on a sub cohort of  
59 children with FCA enrolled in the VIPS study.<sup>14,16</sup> Only children with FCA in AC were  
60 included precluding its utility for posterior circulation stroke.

61 A few case reports have described PVA affecting the PC.<sup>17–19</sup> A study on post-varicella AIS  
62 in Denmark included cases fulfilling clinical and radiologic criteria as well as a positive  
63 cerebrospinal fluid test for varicella-zoster virus (VZV) DNA in combination with intrathecal  
64 VZV IgG production. This includes one case of post-varicella AIS affecting the posterior  
65 circulation.<sup>20</sup> A population-based Swiss study revealed an incidence of PC AIS of 0.18/100  
66 000 children /year. In 25.6% of these cases, the etiology was identified as FCA (FCA-i, FCA-  
67 d and FCA-u).<sup>21</sup> There is currently no scoring system available to describe these cases in  
68 detail.

69 Children with FCA-i mostly present with hemiparesis or hemiplegia.<sup>20,22–24</sup> In general,  
70 children with AIS in the PC show less specific clinical symptoms and signs than those with  
71 AIS in the AC.<sup>21</sup>

72 The aim of our study was to identify all cases of FCA-i in the Swiss NeuroPaediatric Stroke  
73 Registry (SNPSR), to adapt the FCASS to encompass PC FCA-i and to compare clinical and  
74 radiological features of FCA-i between PC and AC.

## 75 **Methods**

### 76 **Patients**

77 We did a retrospective analysis of the prospective nationwide SNPSR which was initiated in  
78 January 2000.<sup>22</sup> It comprises clinical and radiological data on every reported case of  
79 childhood AIS across Switzerland. Hospital-based pediatric neurologists are regularly

reminded to report all pediatric stroke cases to the registry in Bern. The follow-up of these patients is organized centrally from Bern by questionnaires sent to the parents at 2 and 5 years and the clinicians are asked to send in reports from clinical follow up visits according to their local schedule. Short term follow up is usually done by a pediatric neurologist.

The SNPSR has been approved by the competent Ethics Committees and the Swiss Federal Ministry of Health. All registered patients or their legal guardians have provided written informed consent. Details of the SNPSR can be found in previous publications.<sup>22,25</sup> Some patients from the cohort have also been included in previous studies based on the SNPSR.<sup>11,21</sup>

Childhood AIS was defined as a sudden (focal) neurological deficit with radiological proof of an acute ischemic lesion in the corresponding vascular territory. FCA-i included monophasic FCA, as in PVA and TCA.<sup>26</sup>

#### **Inclusion and Exclusion Criteria**

All data of children (aged 1 month-16 years) with AIS registered between January 2000 until December 2018 with available good-quality neuroimaging at diagnosis and follow-up, with documented abnormalities on vascular neuroimaging, were retrospectively reviewed. In addition, charts from children with history of varicella infection within the last 12 months before the stroke were also reviewed.

Inclusion criteria were:

1) childhood stroke due to FCA-i defined by neuroimaging: focal stenosis, irregularity or banding in any vascular territory which was

a) either accompanied by vessel wall contrast enhancement on vessel wall imaging (VWI) or

b) preceded by infection (varicella within 12 months, other infections within weeks before stroke) and in the absence of trauma;



2) monophasic illness without progression on follow-up.

Exclusion criteria were arterial dissections, moyamoya arteriopathy, and underlying systemic disease like bacterial meningitis, neurofibromatosis, Kawasaki disease or systemic lupus erythematosus.

# **Data collection**

Demographic and clinical data, accompanying infectious risk factors and related laboratory investigations, as well as information on the patients' treatment were searched for in the SNPSR. In cases of missing data, the original charts were reviewed. Data on the Pediatric National Institutes of Health Stroke Scale (pedNIHSS) score was collected as reported by the treating physician or performed retrospectively. Neuroimaging was retrospectively analyzed by a trained pediatric neuroradiologist (NS). Pediatric stroke outcome measure (PSOM)<sup>27</sup> was collected from SNPSR or medical charts at discharge, after 6 months (range 3 to 9 months), and after 24 months (range 21 to 27 months). Outcome was dichotomized into good (total PSOM 0–0.5) or poor (total PSOM  $\geq 1$ ).

# **Radiological Scoring of Arteriopathy Severity**

FCASS was applied for assessment of the arteriopathy.<sup>14,16</sup> To measure severity of stenosis in the PC, the same principles were applied to the following segments: intracranial vertebral artery (VA), basilar artery (BA), P1 and P2 segments of the posterior cerebral artery (PCA), the superior cerebellar artery (SCA), the anterior inferior cerebellar artery (AICA) and the posterior inferior cerebellar artery (PICA), see STable 1.

FCASS was assessed on all MR angiography (MRA) and - if MRA was unavailable - on CT angiography (CTA). For further analysis, we included FCASS at baseline, maximum FCASS during follow-up (if more than one measurement available) and final FCASS (if follow-up imaging after > 6 months post stroke was available).

## 127 **Radiological Scoring of infarct Size**

128 Infarct size on admission for AC stroke was calculated using the modified paediatric  
 129 ASPECTS score<sup>28–30</sup> (pedASPECTS), with a maximum of 30 points (15 for each side). Since  
 130 pedASPECTS does not cover most locations in the PC, the modified Bernese diffusion-  
 131 weighted imaging (DWI) score was used for stroke in PC,<sup>31</sup> adding up to a maximum of 22  
 132 points (for details see STable 1).

## 133 **Statistical analyses**

134 First, all variables gathered were analyzed descriptively. The incidence rate of FCA-i in PC in  
 135 Swiss children was calculated using data published by the Swiss Federal Statistical Office<sup>32</sup>.  
 136 We compared the groups where the effects were strictly confined to the anterior or posterior  
 137 circulation. Furthermore, we compared these cases to the group with mixed anterior and  
 138 posterior involvement. If missing data could not be reconstructed retrospectively, patients  
 139 were excluded from analysis. In-Between-group comparison was performed using  
 140 nonparametric statistics (Wilcoxon rank sum and signed rank test). Binary outcomes were  
 141 compared using Fisher's exact test. Correlations between subgroups were evaluated with  
 142 Spearman's correlation coefficient. A 2-sided p-value < 0.05 was considered statistically  
 143 significant. Analysis was performed using R statistical software, version 3.6.1.  
 144 We used the STROBE cohort checklist when writing our report<sup>33</sup>.

## 145 **Data availability**

146 Anonymized raw data is available and can be shared upon reasonable request.

## Results

### Study Population and Epidemiology

During the study period from January 2000 to December 2018, 301 children with AIS aged between 1 month and 16 years were registered in the SNPSR (111 female [36.9%]; median age 5.8 years, IQR 1.9–11.4).

126 cases found in the registry with either documented vascular abnormalities on neuroimaging or an acute VZV infection within 12 months prior to stroke were reviewed clinically. In the first review all cases with a clear diagnosis other than FCA were excluded. The remaining cases underwent a central adjudication of the images.

Ninety children had to be excluded: In 9 cases, intracranial dissection was found to be the cause of FCA (FCA-d) and 11 cases were classified as FCA of undetermined etiology (FCA-u). In 10 cases extracranial dissection of the aorta or the cervical arteries was present, 1 case showed complete occlusion of the internal carotid artery of unknown etiology, and in 10 cases the arteriopathy was due to other types of pathology (e.g., systemic lupus erythematosus, Kawasaki syndrome, trisomy 21, neurofibromatosis type 1, moyamoya disease, and meningitis). Eight children had cardioembolic stroke and 9 children showed progressive central nervous system angiitis. In 32 cases no arteriopathy was found during expert radiological review.

FCA-i was found in 36 children. The total incidence rate of FCA-i in our Swiss cohort was 0.151/ 100 000 children/ year (95%CI 0.109–0.209). AC was affected in 24 children, PC in 7 with an incidence rate of 0.101 (95%CI 0.067-0.150), and 0.029 (95%CI 0.01-0.06) respectively. In 5 cases both circulations were affected with an incidence rate of 0.021 (95%CI 0.008-0.050).

Table 1 displays the baseline characteristics of all patients. Significant differences were found in the initial presentation: Patients with AIS affecting the AC presented more often with facial palsy than those with PC stroke. Headache and tetra paresis were significantly more often reported among cases with posterior FCA-i. Intravenous lysis was performed significantly more often if PC was affected. No between-group differences were found in inclusion criteria, demographic characteristics, and associations with previous infection or outcome.

Children presenting with stroke affecting both circulations did not present with significant differences to the other two groups and this group was excluded from further comparisons.

Details on baseline characteristics, radiological findings, treatment, and outcome are summarized in STable 2.

# **FCASS**

Table 2 summarizes the FCASS obtained in our study for the anterior and the posterior group.

Baseline FCASS was obtained by MRA except in 3 cases of AC by conventional angiography and one case of PC by CTA (early years of the registry). All follow up FCASS were obtained by MRA.

As shown in Table 2, time to final FCASS differed significantly between the posterior and the anterior group with a median time of 300 weeks in the former (IQR 227–351, range 157–359) and 64 weeks (IQR 32 - 169, range 24 - 545) in the latter group ( $p = 0.043$ ). There was no difference in the scores or in the other time periods between the two groups.

Figure 1 shows the evolution of FCASS in the anterior and posterior circulation.

Improvement was evident after 6 months in all cases. The median improvement from baseline to final imaging in AC amounted to 4 points and 5.5 points in PC. Initial worsening seemed

to be more pronounced if PC was affected, but there was no significant difference between groups.

Neither for the anterior nor the posterior group a correlation between pedNIHSS score and FCASS or PSOM and FCASS could be shown. There was also no significant difference between the groups in this regard.

No correlation was evident between FCASS and infarct size. Due to the different scoring system applied, direct comparison of infarct volume between the anterior and the posterior cases was not possible.

## Discussion

The purpose of this study was to characterize cases of inflammation-triggered FCA within the posterior circulation registered in the SNPSR and to compare them to cases of anterior FCA-i. Overall, PC was involved in one third of all FCA-i cases. In keeping with published data on PC- AIS in childhood<sup>17-21</sup> we observed that FCA-i also affects PC in a non-negligible number of patients. Better understanding of the clinical presentation of these cases and application of a scoring system to assess severity of the arteriopathy is needed.<sup>34</sup>

Comparison of cases restricted to PC and AC showed a similar distribution of age. Sex distribution mirrored the typical pattern with more males affected by childhood AIS in general.<sup>22</sup> Similar to PC stroke in general<sup>21,35,36</sup> children with posterior FCA-i presented often with more non-specific symptoms, mainly headache. This group also showed a higher pedNIHSS at presentation. This might be because stroke in the brainstem will present with marked neurological symptoms. Facial palsy was found more often in the anterior group, consistent with the present literature.<sup>21</sup>

The association of VZV infection with FCA-i in the AC was not stronger than in PC. It is hypothesized that upon reactivation of VZV ganglia,<sup>37</sup> the viral capsid might migrate through

axonal retrograde transport (sensory nerve fibers) to the vessel wall of proximal segments of the circle of Willis, replicate and induce a local inflammatory response after transmural spreading. Experimental studies in monkeys demonstrated that intracerebral arteries receive afferent fibers from trigeminal and superior cervical ganglia (harboring latent varicella infection), not only to the carotid T-junction but to a lesser extent also to the posterior, rostral BA, PCA and SCA.<sup>38</sup> A study in rats demonstrated that the first and second spinal ganglion reach intracranial parts of the ipsilateral parts of the ipsilateral vertebral artery as well as the BA (as represented in Figure 2).<sup>39</sup> This explains well the distribution of FCA-i in our study. A major challenge is the distinction between FCA-d and FCA-i.<sup>21</sup> In the early years of the registry FCA-i was not defined or scored. With the goal not to miss any case which in retrospect would be classified as FCA-i, initial inclusion criteria were taken very broad. This explains why so many cases had to be excluded upon clinical and radiological review. All FCA cases were reviewed for the typical signs of dissections like ectasia, fusiform aneurysm, intimal flap, intramural hematoma or pseudoaneurysm. Consistent with the literature, history of head trauma was considered to support diagnosis of FCA-d.<sup>1</sup> The presence of multiple lesions (as typical for PC cases) makes the diagnosis of a dissection very unlikely. Additionally, all lesions in our cases are localized in the typical region of the wandering of virus along sympathetic and sensory fibers as discussed before. In the cases affecting the BA the length of the lesion present is very atypical for an intracranial dissection. Considering all these points, we are convinced that our 7 cases in the posterior circulation are in fact FCA-i and with a high degree of confidence not FCA-d. Concerning the difficulty of making a diagnosis of FCA-i we conclude that vessel wall imaging is needed if FCA-i is suspected, and special attention should be paid to the localization and the presence of multiple lesions.

Only one of our cases was associated with Lyme neuroborreliosis (LNB) and affected solely the PC, as most of the cases reported in the literature.<sup>11</sup> Notably, this patient (case 25, STable 2) presented with mild symptoms only, but imaging studies revealed involvement of multiple arteries of the PC. This is in line with the pathophysiological hypothesis that the family Spirochaetaceae may induce perivascular inflammation rather than transport of infectious triggers via nerve fibers to vessels. A synopsis of published cases of LNB associated with pediatric stroke<sup>11</sup> and our data strongly suggest that testing for LNB should be performed in cases of FCA-i- especially affecting the PC and multiple arterial segments.

Regarding treatment, intravenous thrombolysis was more often performed when the PC was affected, reflecting the severity of the acute disease, especially when BA was involved. Due to lack of randomized controlled trials on recanalization therapy in children with AIS, recommendations rely mainly on expert opinion.<sup>40</sup> In the treatment of FCA-i, we consider that mechanical thrombectomy should be indicated very cautiously and only in selected patients with major vessel occlusion (e.g., carotid-T or M1). Interventions in vessels with underlying vessel wall inflammation may lead to unsuccessful recanalization and/or periprocedural complications. Intravenous or intraarterial thrombolysis (distant to local lesion) should be preferred over thrombectomy.

Median PSOM after 6 and 12 months was higher in the posterior group in our sample (Table 1), but the difference did not reach statistical significance, presumably due to the underpowered nature of the study. The median PSOM was 1 in cases of AC- and PC-FCA-i. This is in line with the original VIPS study.<sup>41</sup>

To score the extent of arteriopathy in the PC, we adapted the FCASS to fit PC-FCA. A validation of the posterior FCASS is not possible due to the small number of cases but would be desirable with a larger number of patients.

Previous FCASS studies have reported a positive correlation between infarct size and FCASS. The original FCASS study also found a correlation between higher 1-year PSOM and greater maximum FCASS, which could not be replicated in the Swiss study.<sup>16</sup>

We found no correlation between infarct size and FCASS or between PSOM and FCASS in cases involving the PC. Part of the explanation may be the different association between infarct size and clinical outcome in PC due to anatomical features and different dimensions. Further, the small sample size may well have prevented detection of possible correlations.

The most important limitation of our study is the small sample size, which makes comparison and correlation difficult. Even over this large time span, only a few cases of FCA-i within the PC were registered in Switzerland.

Because of the small sample size, significance levels must be interpreted with caution. However, we still consider our sample representative. Given the acquisition process and the well-established status of the SNPSR, we are convinced that most cases of childhood AIS during this time would have been captured. Thus, the conclusions drawn from our study still provide a solid basis for clinical decisions, highlighting the need for prospective randomized trials, especially regarding treatment regimens.

Another limitation is the lack of standardized guidelines for follow-up imaging. Since this is a retrospective analysis of a population-based registry and the patients were recruited over a long period of time, the availability of imaging studies and the imaging protocols have changed and differ between cases. To appreciate vessel wall enhancement, dedicated VWI is crucial, but was performed at presentation in only a minority of cases. According to the imaging recommendations, VWI is not necessarily performed in the acute setting<sup>42</sup> although it can differentiate between the types of FCA.



288 We conclude that FCA-i occurs in the PC alone or in combination with FCA-i in the AC,  
 289 although less often than isolated AC involvement. Thus, further studies in this field should  
 290 consider including cases of FCA-i in PC. Children with posterior FCA-i present more often  
 291 with non-specific symptoms. The modified FCASS may well serve as a marker for the  
 292 evolution of disease but needs validation in another cohort. VWI is crucial in evaluating  
 293 children presenting with PC stroke and should be included in stroke protocols.

## Acknowledgements

We thank all participants of the Swiss NeuroPaediatric Stroke Registry as well as their parents.

We thank Heather J Fullerton (UCSF) for her valuable input in the discussion and Mr. Charles Grose from University of Iowa Hospital, Iowa City to point our interest to the explanations of localizations of FCA-i; all the coworkers of the SNPSR: Andrea Capone Mori (Aarau), Alexandre Datta (Basel), Joël Fluss (Geneva), Annette Hackenberg (Zürich), Elmar Keller (Chur), Oliver Maier (St. Gallen), Jean-Pierre Marcoz (Sion), Claudia Poloni (Lausanne), Gian Paolo Ramelli (Bellinzona), Regula Schmid (Winterthur), and Thomas Schmitt-Mechelke (Lucerne).

## Sources of Funding

The work within the Swiss Neuropaediatric Stroke Registry (SNPSR) has been supported by Novartis Research Foundation, Swiss Heart Foundation, Foundation for neuropsychiatric research, Fondazione Ettore e Valeria Rossi, Anna Mueller Grocholski Stiftung, batzebar Kinderkliniken Bern.

## Disclosures

The authors report no other financial disclosures relevant to the manuscript.

## Supplemental Material

- Supplemental Table S1a: Extended FCASS for the anterior and posterior circulation
- Supplemental Table S1b. Modified Bernese Posterior Stroke Score
- Supplemental Table S1c. Modified pedASPECTS
- Supplemental STable 2: Detailed Results
- Supplemental SFigure 1. Example of acute imaging in strictly posterior involvement

## References

1. Wintermark M, Hills NK, DeVeber GA, Barkovich AJ, Bernard TJ, Friedman NR, et al. Clinical and Imaging Characteristics of Arteriopathy Subtypes in Children with Arterial Ischemic Stroke: Results of the VIPS Study. *American Journal of Neuroradiology* 2017;38:2172–2179.
2. Chabrier S, Rodesch G, Lasjaunias P, Tardieu M, Landrieu P, Sébire G. Transient cerebral arteriopathy: A disorder recognized by serial angiograms in children with stroke. *J Child Neurol* 1998;13:27–32.
3. Sébire G, Fullerton H, Riou E, DeVeber G. Toward the definition of cerebral arteriopathies of childhood. *Curr Opin Pediatr* 2004;16:617–22.
4. Sébire G, Meyer L, Chabrier S. Varicella as a risk factor for cerebral infarction in childhood: A case-control study. *Ann Neurol* 1999;45:679–680.
5. Berger TM, Caduff JH, Gebbers JO. Fatal varicella-zoster virus antigen-positive giant cell arteritis of the central nervous system. *Pediatric Infectious Disease Journal* 2000;19:653–656.
6. Elkind MSV, Hills NK, Glaser CA, Lo WD, Amlie-Lefond C, Dlamini N, et al. Herpesvirus Infections and Childhood Arterial Ischemic Stroke: Results of the VIPS Study. *Circulation* 2016;133:732–741.
7. Ganesan V, Prengler M, McShane MA, Wade AM, Kirkham FJ. Investigation of risk factors in children with arterial ischemic stroke. *Ann Neurol* 2003;53:167–173.
8. Monteventi O, Chabrier S, Fluss J. Prise en charge diagnostique et thérapeutique actuelle des accidents vasculaires cérébraux post-varicelleux chez l'enfant: Revue de la littérature. *Archives de Pédiatrie* 2013;20:883–889.

9. Piccolo B, Barsacchi M, Greco F, Cerasti D, Ormitti F, Pisani F. Transient posterior cerebral arteriopathy: An unusual case enterovirus-related. *Brain Dev* 2019;41:214–216.
10. Socan M, Ravnik I, Bencina D, Dovc P, Zakotnik B, Jazbec J. Neurological Symptoms in Patients Whose Cerebrospinal Fluid Is Culture- and/or Polymerase Chain Reaction-Positive for *Mycoplasma pneumoniae*. *Clinical Infectious Diseases* 2001;32:e31–e35.
11. Monteventi O, Steinlin M, Regényi M, Roulet-Perez E, Weber P, Fluss J. Pediatric stroke related to Lyme neuroborreliosis: Data from the Swiss NeuroPaediatric Stroke Registry and literature review. *European Journal of Paediatric Neurology* 2018;22:113–121.
12. Amlie-Lefond C, Bernard TJ, Sébire G, Friedman NR, Heyer GL, Lerner NB, et al. Predictors of Cerebral Arteriopathy in Children With Arterial Ischemic Stroke. *Circulation* 2009;119:1417–1423.
13. Braun KPJ, Bulder MMM, Chabrier S, Kirkham FJ, Uiterwaal CSP, Tardieu M, et al. The course and outcome of unilateral intracranial arteriopathy in 79 children with ischaemic stroke. *Brain* 2009;132:544–557.
14. Fullerton HJ, Stence N, Hills NK, Jiang B, Amlie-Lefond C, Bernard TJ, et al. Focal Cerebral Arteriopathy of Childhood: Novel Severity Score and Natural History. *Stroke* 2018;49:2590–2596.
15. Steinlin M, Bigi S, Stojanovski B, Gajera J, Regényi M, El-Koussy M, et al. Focal Cerebral Arteriopathy: Do Steroids Improve Outcome? *Stroke* 2017;48:2375–2382.
16. Slavova N, Fullerton HJ, Hills NK, Breiding PS, Mackay MT, Steinlin M. Validation of the focal cerebral arteriopathy severity score (FCASS) in a Swiss cohort:

Correlation with infarct volume and outcome. *European Journal of Paediatric Neurology* 2020;28:58–63.

17. Ganesan V, Kirkham FJ. Mechanisms of ischaemic stroke after chickenpox. *Arch Dis Child* 1997;76:522–525.
18. Shuper A, Vining EPG, Freeman JM. Central nervous system vasculitis after chickenpox - Cause or coincidence? *Arch Dis Child* 1990;65:1245–1248.
19. Sträter R, Becker S, Von Eckardstein A, Heinecke A, Gutsche S, Junker R, et al. Prospective assessment of risk factors for recurrent stroke during childhood - A 5-year follow-up study. *Lancet* 2002;360:1540–1545.
20. Helmuth IG, Mølbak K, Uldall PV, Poulsen A. Post-varicella Arterial Ischemic Stroke in Denmark 2010 to 2016. *Pediatr Neurol* 2018;80:42–50.
21. Fink M, Slavova N, Grunt S, Perret E, Regényi M, Steinlin M, et al. Posterior Arterial Ischemic Stroke in Childhood. *Stroke* 2019;50:2329–2335.
22. Steinlin M, Pfister I, Pavlovic J, Everts R, Boltshauser E, Mori AC, et al. The first three years of the Swiss Neuropaediatric Stroke Registry (SNPSR): A population-based study of incidence, symptoms and risk factors. *Neuropediatrics* 2005;36:90–97.
23. Miravet E, Danchaivijitr N, Basu H, Saunders DE, Ganesan V. Clinical and radiological features of childhood cerebral infarction following varicella zoster virus infection. *Dev Med Child Neurol* 2007;49:417–422.
24. MacKay MT, Wiznitzer M, Benedict SL, Lee KJ, Deveber GA, Ganesan V. Arterial ischemic stroke risk factors: The international pediatric stroke study. *Ann Neurol* 2011;69:130–140.

25. Pavlovic J, Kaufmann F, Boltshauser E, Capone Mori A, Gubser Mercati D, Haenggeli CA, et al. Neuropsychological problems after paediatric stroke: Two year follow-up of Swiss children. *Neuropediatrics* 2006;37:13–19.
26. Rafay MF, Shapiro KA, Surmava AM, deVeber GA, Kirton A, Fullerton HJ, et al. Spectrum of cerebral arteriopathies in children with arterial ischemic stroke. *Neurology* 2020;94:e2479–e2490.
27. Kitchen L, Westmacott R, Friefeld S, MacGregor D, Curtis R, Allen A, et al. The pediatric stroke outcome measure: A validation and reliability study. *Stroke* 2012;43:1602–1608.
28. Barber PA, Demchuk AM, Zhang J, Buchan AM. Validity and reliability of a quantitative computed tomography score in predicting outcome of hyperacute stroke before thrombolytic therapy. *The Lancet* 2000;355:1670–1674.
29. Beslow LA, Vossough A, Dahmouch HM, Kessler SK, Stainman R, Favilla CG, et al. Modified pediatric ASPECTS correlates with infarct volume in childhood arterial ischemic stroke. *Front Neurol* 2012;JUL.
30. Mackay MT, Slavova N, Pastore-Wapp M, Grunt S, Stojanovski B, Donath S, et al. Pediatric ASPECTS predicts outcomes following acute symptomatic neonatal arterial stroke. *Neurology* 2020;94:e1259–e1270.
31. Karameshev A, Arnold M, Schroth G, Kappeler L, Stein P, Gralla J, et al. Diffusion-Weighted MRI Helps Predict Outcome in Basilar Artery Occlusion Patients Treated with Intra-Arterial Thrombolysis. *Cerebrovascular Diseases* 2011;32:393–400.
32. Bundesamt für Statistik.  
<https://www.bfs.admin.ch/bfs/de/home/statistiken/bevoelkerung.html>. Accessed June 27, 2019.

33. von Elm E, Altman D, Egger M, Pocock S, Gøtzsche P, Vandenbroucke J. The Strengthening the Reporting of Observational Studies in Epidemiology (STROBE) Statement: guidelines for reporting observational studies. 2020.
34. Steinlin M, O’callaghan F, Mackay MT. Planning interventional trials in childhood arterial ischaemic stroke using a Delphi consensus process. *Dev Med Child Neurol* 2017;59:713–718.
35. Mackay MT, Prabhu SP, Coleman L. Childhood Posterior Circulation Arterial Ischemic Stroke. *Stroke* 2010;41:2201–2209.
36. Goeggel Simonetti B, Rafay MF, Chung M, Lo WD, Beslow LA, Billingham LL, et al. Comparative study of posterior and anterior circulation stroke in childhood: Results from the International Pediatric Stroke Study. *Neurology* 2020;94:e337–e344.
37. Grose C, Shaban A, Fullerton HJ. Common Features Between Stroke Following Varicella in Children and Stroke Following Herpes Zoster in Adults : Varicella-Zoster Virus in Trigeminal Ganglion. *Curr Top Microbiol Immunol* 2023;438:247–272.
38. Simons T, Ruskell GL. Distribution and termination of trigeminal nerves to the cerebral arteries in monkeys. *J Anat* 1988;159:57.
39. Arbab MAR, Wiklund L, Svendgaard NA. Origin and distribution of cerebral vascular innervation from superior cervical, trigeminal and spinal ganglia investigated with retrograde and anterograde WGA-HRP tracing in the rat. *Neuroscience* 1986;19:695–708.
40. Sporns PB, Fullerton HJ, Lee S, Kim H, Lo WD, Mackay MT, et al. Childhood stroke. *Nat Rev Dis Primers* 2022;8.
41. Fullerton HJ, Stence N, Hills NK, Jiang B, Amlie-Lefond C, Bernard TJ, et al. Focal Cerebral Arteriopathy of Childhood. *Stroke* 2018;49:2590–2596.

42. Mirsky DM, Beslow LA, Amlie-Lefond C, Krishnan P, Laughlin S, Lee S, et al.  
Pathways for Neuroimaging of Childhood Stroke. *Pediatr Neurol* 2017;69:11–23.



**Table 1 Summarized baseline characteristics of the patients**

<b>Inclusion criteria</b>	<b>Anterior circulation FCA-i [N = 24]</b>	<b>Posterior circulation FCA-i [N = 7]</b>	<b>Differences between anterior and posterior FCA-i, p-values</b>	<b>Both anterior and posterior circulation FCA-i [N = 5]</b>	<b>Difference between anterior and posterior FCA-i versus FCA-i in both circulations, p- values</b>
Typical course of FCA, N(%)	18 (75.0)	6 (85.7)	0.51 (0.01-5.79, p=1)*	5 (100.0)	Inf (0.21-inf, p=0.559)*
Vessel wall enhancement, N(%)	6 (25.0)	0 (0.0)	Inf (0.35-inf, p=0.292)*	1 (20.0)	1.04 (0.02-13.50, p=1)*
Proven infection†, N(%) History of infection present in 36/36	13 (54.2)	3 (42.9)	1.55 (0.21–13.00, p=0.69)*	4 (80.0)	3.63 (0.31-196.54, p=0.350)*
<b>Demographic characteristics</b>					
Age, y, median (IQR)	6.4 (2.5–8.6)	6.7 (5.7–8.0)	0.56 (–2.2–4.0, p=0.586) <sup>‡</sup>	2.9 (1.7–6.3)	2.60 (–2.0–5.40, p=0.410) <sup>‡</sup>
Male, N(%)	13 (54.2)	4 (57.1)	0.88 (0.11–6.58, p=0.889)*	4 (80.0)	3.20 (0.27–173.4, p=0.376)
<b>Symptoms at presentation</b>					
pedNIHSS, median (IQR)	4.5 (2.0–8.0)	8.0 (5.0–18.0)	4.00 (–2.00–14.00, p=0.162) <sup>‡</sup>	6.0 (6.0–6.0)	–1.00 (–4.0–4.0, p=0.854) <sup>‡</sup>
Hemiparesis, N(%)	20 (83.3)	4 (57.1)	3.56 (0.38–32.77, p=0.302)*	4 (80.0)	1.16 (0.09–65.53, p=1)*
Quadriparesis, N(%)	0 (0.0)	2 (28.6)	0 (0–1.44, p=0.045)*	0 (0.0)	0 (0–35.53, p=1)*

Facial palsy	19 (79.2)	2 (28.6)	8.65 (1.04–117.05, p=0.021)*	4 (80.0)	1.87 (0.16–102.99, p=1)*
Altered consciousness	5 (20.8)	3 (42.9)	0.365 (0.04–3.31, p=0.336)*	0 (0.0)	0 (0–2.87, p=0.566)*
Headache	6 (25.0)	7 (100.0)	0 (0–0.33, p=0.001)*	2 (40.0)	0.93 (0.07–9.33, p=1)*
Nausea/vomiting	8 (33.3)	5 (71.4)	0.21 (0.02–1.64, p=0.099)*	1 (20.0)	0.36 (0.01–4.17, p=0.628)*
Ataxia	1 (4.2)	2 (28.6)	0.12 (0.00–2.71, p=0.12)*	0 (0.0)	0 (0–16.87, p=1)*
Vertigo	2 (8.3)	2 (28.6)	0.24 (0.01–4.07, p=0.21)*	0 (0.0)	0 (0–10.74, p=1)*
Seizure	4 (16.7)	2 (28.6)	0.51 (0.05–7.19, p=0.596)*	1 (20.0)	1.04 (0.02–13.50, p=1)*
Fever	2 (8.3)	1 (14.3)	0.56 (0.02–37.49, p=0.557)*	0 (0.0)	0 (0–16.87, p= 1)*
<b>Association with infections</b>					
VZV within previous 12 months, N(%)	14 (58.3)	2 (28.6)	3.36 (0.44–42.07, p=0.230)*	3 (60.0)	1.39 (0.14–18.90, p=1)*
Borrelia burgdorferi, N(%)	0 (0.0)	1 (14.3)	0 (0–11.38, p=1)*	0 (0.0)	0 (0–240.89, p=1)*
Other infections, N(%)	9 (37.5)	4 (57.1)	0.46 (0.05–3.43, p=0.413)*	2 (40.0)	0.93 (0.07–9.33, p=1)*
<b>Treatment</b>					
ASA monotherapy, N(%)	9 (37.5)	2 (28.6)	0.95 (0.13–8.00, p=1)*	1 (20.0)	0.36 (0.01–4.17, p=0.628)*
Combinations, N(%)	14 (58.3)	2 (28.6)	3.36 (0.44–42.07,	4 (80.0)	3.63 (0.31–196.54,

			p=0.220)*		p=0.355)*
ASA + Heparin/LMWH, N(%)	1 (4.2)	1 (14.3)	0.41 (0.00–23.86, p=0.41)*	0 (0.0)	0 (0–35.53, p=1)*
ASA + steroids, N(%)	3 (12.5)	1 (14.3)	0.86 (0.06–52.41, p=1)*	2 (40.0)	4.25 (0.28–51.96, p=0.186)*
ASA + acyclovir, N(%)	3 (12.5)	0 (0.0)	Inf (0.11–inf, p=1)*	0 (0.0)	0 (0–16.87, p=1)*
ASA + steroids + acyclovir, N(%)	6 (25.0)	0 (0.0)	Inf (0.35–inf, p=0.203)*	1 (20.0)	1.04 (0.02–13.50, p=1)*
ASA + heparin/LMWH + steroids + acyclovir, N(%)	0 (0.0)	0 (0.0)	-	1 (20.0)	Inf (0.16–Inf, p=0.139)*
Heparin/LMWH + steroids, N(%)	1 (4.2)	0 (0.0)	Inf (0.01–inf, p=1)*	0 (0.0)	0 (0–240.89, p=1)*
IV lysis, N(%)	1 (4.2)	3 (42.9)	0.07 (0.00–1.05, p=0.027)*	0 (0.0)	0 (0–10.74, p=1)*
<b>Outcome</b>					
PSOM discharge, median(IQR)[N]	1.0 (0.5–2.0)[24]	1.0 (0.25– 4.8)[7]	0.50 (–1.00–3.50, p=0.597) <sup>‡</sup>	1.0 (0.5– 3.0)[5]	–0.00 (2.00–1.00, p=0.816) <sup>‡</sup>
PSOM 6 months, median(IQR)[N]	0.5 (0.0–1.0)[21]	1.5 (0.5–4.0)[7]	1.00 (–0.50–3.00, p=0.165) <sup>‡</sup>	1.5 (0.0– 2.5)[5]	0.00 (–2.50–0.50, p=0.681) <sup>‡</sup>
PSOM 24 months, median(IQR)[N]	0.5 (0.0–1.0)[20]	1.25 (0.1– 2.8)[6]	0.50 (–0.50–2.50, p=0.490) <sup>‡</sup>	0.5 (0.3– 2.3)[3]	0.00 (–3.50–1.50, p=0.941) <sup>‡</sup>
Death, N(%)	0 (0.0)	0 (0.0)	–	0 (0.0)	–

Recurrence, N(%)	1 (4.2)	1 (14.3)	0.28 (0.00–23.86, p=0.406)*	0 (0.0)	0 (0–35.53, p=1)*
------------------	---------	----------	--------------------------------	---------	-------------------

FCA = focal cerebral arteriopathy; y = years; IQR = interquartile range; pedNIHSS = pediatric National Institutes of Health Stroke Scale; ASA = acetyl salicylic acid; LMWH = low-molecular-weight heparin; PSOM = pediatric stroke outcome measure; Inf = infinity; VSV = varicella-zoster virus.

\*Fisher's exact test: OR (95% confidence interval, two tailed p-value). †By serology or PCR. Wilcoxon Rank Sum test: difference in location (95% confidence interval, tow tailed p-value).

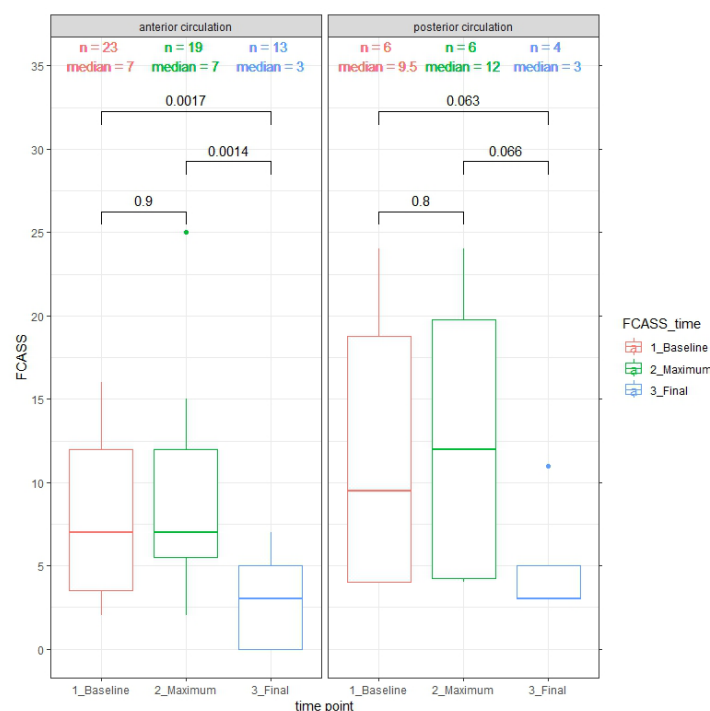
**Table 2 Focal Cerebral Arteriopathy Severity Score (FCASS) summary at different time points**

	Posterior circulation		Anterior circulation	
	Time after stroke in days, median (IQR),[N]	Score, median (IQR)	Time after stroke in days, median (IQR),[N]	Score, median (IQR)
FCASS baseline	1.0 (0.25–13.0),[6]	9.5 (4.0–18.75)	1.0 (0.0–10.0),[23]	7.0 (3.5–12.0)
FCASS maximum	15.5 (4.25–17.75),[6]	12.0 (4.25–19.75)	1.0 (1.0–7.5),[19]	7.0 (5.5–12.0)
FCASS final	2098 (1592–2458),[4]	3.0 (3.0–5.0)	451 (226–1185),[13]	3.0 (0.0–5.5)

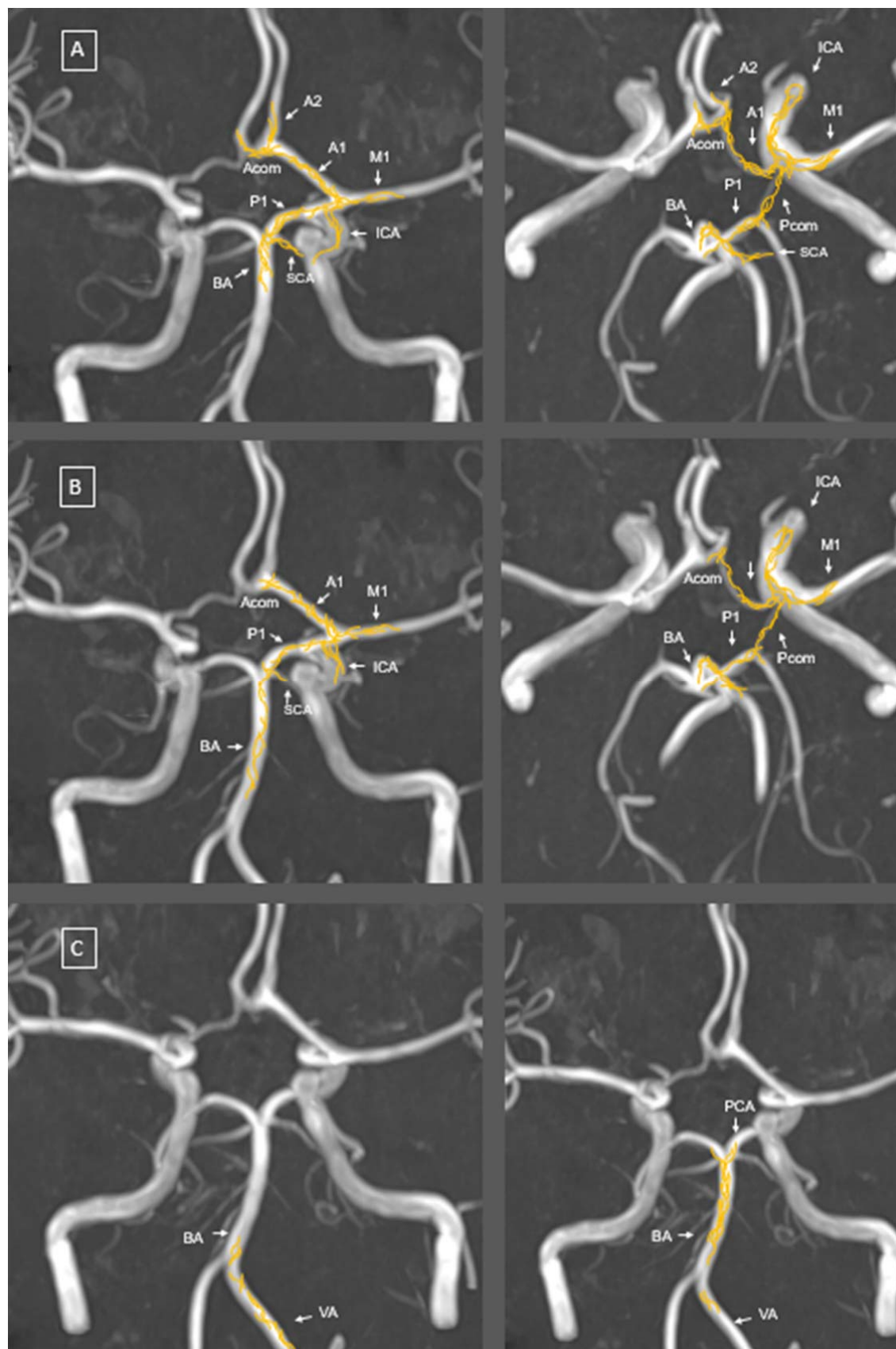
FCASS baseline = FCASS of the first available imaging after stroke; FCASS maximum = highest FCASS of all available imaging – only for those patients with serial neuroimaging; FCASS final = FCASS of last imaging – only if imaging more than 24 weeks post-stroke was available; IQR = interquartile range; N = number of available FCASS in this group.

## Figures

Figure 1: Baseline maximum and final FCAS-Score



Comparison by Wilcoxon rank sum and signed rank test; 2-sided p-value indicated.



## Figure 2. Schematic representation of nerve fibre distribution

Adapted from Arbab et al. using neuroanatomical tracing techniques after tracer injection into

A) the trigeminal ganglion, B) the superior cervical ganglion and C) first (left image) and second (right image) spinal ganglia. The distribution of the anterogradely labelled nerve fibres (in yellow) was mapped on time-of-flight magnetic resonance angiography (MRA) maximum intensity projection (MIP) reconstruction imaging of the cerebral blood vessels.

ACA, anterior cerebral artery; Acom, anterior communicating artery; BA, basilar artery; ICA, internal carotid artery; MCA, middle cerebral artery; PCA, posterior cerebral artery; Pcom, posterior communicating artery; SCA, superior cerebellar artery; VA, vertebral artery.