

Morphological changes in the mandible associated with the presence of exostoses: a study in two archaeological populations from southern France.

Estelle Casazza^{1*}, Benoit Ballester², Camille Philip-Alliez³, Yann Ardagna⁴, Anne Raskin¹

¹ Aix Marseille University, APHM, CNRS, EFS, ADES, Marseille, France.

² Aix Marseille University, APHM, INSERM, IRD, SESSTIM, ISSPAM, Marseille, France.

³ Aix Marseille University, APHM, University Gustave Eiffel, LBA, Marseille, France.

⁴ Aix Marseille University, CNRS, EFS, ADES, Marseille, France.

* Corresponding author

E-mail: estelle.casazza@ap-hm.fr (EC)

Author contributions

EC: Conceptualization, Investigation, Methodology, Writing

BB: Investigation and Formal Analysis

YA: Project Administration and Resources

CPA: Visualization

AR: Methodology, Supervision and Validation

Abstract

This study aimed to investigate morphological changes in the mandible of subjects in archaeological collections associated with the presence of bony exostoses at the mandibular angle, which are described in the literature as related to specific behaviours of the manducatory apparatus like parafunctional activities. The skeletal sample investigated comprised adult individuals from two archaeological series. Sixteen measurements of the mandible were selected to evaluate anatomic variation in the two populations. Mandibles from both series were pooled for statistical analysis into two groups according to the number of exostoses at the mandibular angles: group 1 (number of exostoses ≤ 1) and group 2 (number of exostoses ≥ 2). Measurements could be made on eighty mandibles. A statistically significant difference was demonstrated between group 1 and group 2 for the following

NOTE: This preprint reports new research that has not been certified by peer review and should not be used to guide clinical practice.

parameters: distance between mandibular angles, bicondylar width, ramus height, left condyle length, right and left coronoid process height. For each of these parameters, values were higher in group 2 than in group 1. This study presents an original methodology for studying anatomical variations of the mandible in the context of parafunctional activity, highlighting certain mandibular modifications. The impact of parafunctional behaviours such as bruxism on the mandible therefore has many anatomical expressions. The considerable variability of results found in the literature shows that more studies are needed to reach a consensus on the impact of parafunctional activities on the mandible.

Keywords: mandible, exostoses, mandibular angle, archaeological population, oral parafunction, bruxism

Introduction

The mandible, the only mobile bone in the skull, consists of three parts: the body (corpus) and two rami, connected by two mandibular angles. Like all skeletal bones, the mandible is constantly remodelled under the effect of several factors, which may be systemic (e.g. hormones, growth factors) or local (e.g. mechanical stresses) resulting from the action of the muscles of the manducatory apparatus [1–3]. Several muscles insert on the mandible to support the functions of mastication, swallowing, phonation, and emotion management. These include the mandibular elevator and depressor muscles, and those responsible for mandibular propulsion [4], which insert at various mandibular levels and connect the mandible to the facial skeleton.

Bone remodelling induced by mechanical stress was described as early as 1892 by Wolff, who noted that “bone in a healthy person or animal adapts to the forces to which it is subjected”[5]. Bone can respond locally to the mechanical stresses to which it is subjected, via cellular adaptation mechanisms [6]. Several types of bone response have been described. If appropriate mechanical stresses are applied, bone mass may increase. However, if the mechanical stresses applied are too great, there may be a reduction in bone mass through increased resorption, with a risk of fatigue fracture. On the other hand, if the bone is not stressed, or is immobilised, it exhibits a high level of resorption with a concomitant reduction in bone formation [7].

Assessment of mandibular bone remodelling involves the evaluation of mandibular volume. Here, researchers have several options: the use of radiological imaging derived from medical activity, which requires the use of slices in all three spatial planes [8]; accessing bodies donated to science, which presents difficulties of access and implementation (e.g. preparation of parts); the study of archaeological series, which is dependent on the excavation conditions and state of preservation of the individuals recovered.

While the study of archaeological series deprives the researcher of access to certain data on the subjects investigated, it does allow measurements to be collected directly from the mandible, when its state of preservation permits. This has allowed the evaluation of mandibular markers, described in the literature as related to specific behaviours of the manducatory apparatus. This is the case for exostoses that may be present at the mandibular angles [9]. Their location corresponds to the lower insertion zones of the masseter muscle, the most powerful elevator muscle in the manducatory apparatus [10]. These exostoses develop when repeated muscular forces are applied through frequent contraction of the masseter muscles [11]. Several exostoses may be found at the same angle. The number of these exostoses reflects both the intensity of the forces exerted on the mandible in this area, and the high frequency with which these forces occur in the life of the individual, exceeding those ordinarily applied for manducatory functions alone, and potentially reflecting parafunctional behaviours established in the manducatory apparatus of the individuals observed [12].

This study aimed to investigate morphological changes in the mandible of subjects in archaeological collections associated with the presence of bony exostoses at the mandibular angle.

Materials and Methods

Skeletal samples

This study was conducted with ethical approval from the SRA DRAC-PACA, French Ministry of Culture. The skeletal sample investigated comprised adult individuals from two archaeological series,

Les petites Crottes (Bouches-du-Rhône, Marseille, Old cemetery of Crottes, 2016, 10 461), and L'îlot Saint Jacques (Bouches-du-Rhône, La Ciotat, Carré Saint Jacques, 2011). Both collections are held at the SRA DRAC PACA Osteotheque and were studied on site.

Description of archaeological sites

The Petites Crottes sample, dated from 1784 to 1905, was excavated from a parish cemetery in North Marseille, in southern France. Excavations took place in 2013 and 2014 [13]. The field study population consisted of 1,548 individuals; 532 subjects were studied in the laboratory [14]. Adult sex was evaluated in most cases by an assessment of the coxal bone using Bruzek's morphoscopic method [15] and probabilistic sex diagnosis or PSD [16]. Age at death of adult subjects was estimated by noting the bone maturity status of the clavicle and the coxal bone, degenerative pathologies, and dental status (attrition, ante-mortem tooth loss, etc.). Adult subjects were divided into three age classes: young adults (20-39 years), mature adults (40-59 years), and elderly adults (> 60 years).

The Ilot Saint-Jacques sample came from a parish cemetery, in use from 1581 to 1831, in the town of La Ciotat, in southern France. Excavations took place in 2009 [17]. The population studied in the field comprised 1,245 individuals; 400 subjects were studied in the laboratory. Biological parameters were investigated using techniques identical to those described for the first series.

Sample selection

The first phase of selection of individuals from the subjects preserved in the SRA DRAC PACA Osteotheque was based on the individual osteological conservation sheets taken from the excavation reports for the two archaeological sites, according to the following criteria:

Subject inclusion criteria

- Adult individual,
- With or without a sex diagnosis,
- Presenting a completely intact mandible OR presenting a mandible with a single post-mortem bone fracture allowing anatomical reassembly of the two fragments present OR an incomplete

mandible missing a single mandibular anatomical element such as a condyle, coronoid process,
or mandibular angle (right or left).

Criteria for non-inclusion of subjects

- Immature subject,
- Presence of temporary teeth on an arch,
- Mandible absent,
- Mandible deterioration: in more than two pieces, several fragments missing,
- Edentulous mandible (ante-mortem closure of dental sockets).

In the second phase the collections were examined, and the subjects listed in the initial excavation report
file as meeting the inclusion criteria but presenting significant deterioration of the mandible objectified
during the examination were excluded.

Methods

Measurements made on archaeological series

Some of the measurements made were based on previously defined procedures for dry bone,
except for condylar and coronoid process measurements [18,19]. Sixteen measurements of the mandible
were selected to evaluate anatomic variation in the two populations:

- Chin height, right side
- Corpus height, right side
- Corpus width, right side
- Bigonial breadth
- Bicondylar breadth
- Minimum ramus width, right side
- Maximum ramus height, right side
- Corpus length, right side
- Mandibular angle, both side

131 - Maximum width of right and left condyles

132 - Maximum length of right and left condyles

133 - Presence and number of exostoses at the mandibular angles

134 - Height of right and left coronoid processes

135 Measurements and their definitions are indicated in Figs 1a, 1b, 1c and 1d.

136

137 **Fig 1a (SP 545, Les petites Crottes collection). Measurements in the frontal plane.**

138 (a) chin height. (b) corpus height. (c) corpus width. (d) distance between mandibular angles. (e)

139 bicondylar width.

140

141 **Fig 1b (SP 460, Ilot Saint Jacques collection). Measurements in the sagittal plane.**

142 (f) minimum ramus width. (g) maximum ramus height. (h) corpus length. (i) mandibular angle. (j) right

143 coronoid process height.

144 **Fig 1c (SP 545, Les petites Crottes collection). Measurements in the horizontal plane.**

145 (k) maximum right condyle length. (l) maximum right condyle width. (m) maximum left condyle length.

146 (n) maximum left condyle width.

147

148 **Fig 1d (SP 545, Les petites Crottes collection). Presence of exostosis at the mandibular angle.**

149 (o) exostosis at the mandibular angle

150

151 These measurements were performed by two calibrated operators. Measurements were recorded

152 using sliding callipers, with readings being taken to the nearest 0.01 mm, while a mandibulometer was

153 used to measure the mandibular angle. Not all measurements were recorded on every individual due to

154 the incomplete or fragmentary condition of the remains. Nevertheless, most measurements could be

155 recorded on all individuals. Measurements recorded on parts exhibiting taphonomic, traumatic, or

156 pathologic changes were only included if they did not affect the measurement. The missing data rate for

each parameter studied was recorded (ratio of the number of mandibles on which the parameter was measured to the total number of mandibles studied).

Statistical methods

Analyses were performed using R software (version 4.0.3), available at <https://www.r-project.org>.

Evaluator calibration

To check evaluator reliability (intra-operator variability) and method reproducibility (inter-operator variability), a Bland–Altman agreement test was performed on quantitative data, and a weighted Cohen’s Kappa test was run on the presence of bony exostoses at the mandibular angle, as the test was carried out on two ordinal samples.

Sample analysis

Mandibles from both series were pooled for statistical analysis. These were divided into two groups according to the number of exostoses at the mandibular angle:

- Group 1: total number of exostoses at the two mandibular angles, 0 or 1.

- Group 2: total number of exostoses at the two mandibular angles, greater than or equal to 2.

The F-test for equality of two variances was used to verify normal distribution and the equality of variances between the two groups.

An analysis was carried out on the whole sample using Welch's t-test to study the correlations between the presence of exostoses at the mandibular angle and the dimensional variation of the 15 mandibular parameters investigated.

Results

Sample composition

Measurements could be made on only 50 of the 102 adult subjects in the Petites Crottes series, selected initially on the basis of the excavation report.

Measurements could be made on only 30 of the 43 adult subjects in the Îlot St Jacques series selected initially on the basis of the excavation report.

Biological parameters and the number of exostoses found for the 80 subjects studied are shown in Fig 2.

Fig 2. Distribution of individuals according to sex, age, and presence of exostoses at the mandibular angle.

The sample comprised 29 males, 19 females, and 32 subjects of undetermined sex. Of these, 42 had a total of 0 or 1 mandibular angle exostoses for both angles (group 1), and 38 had a total of 2 or more mandibular angle exostoses for both angles (group 2).

Evaluator calibration

There was a good agreement of all 1200 quantitative measurements made by the two operators (Bland–Altman tests), both in terms of repeatability for each operator (Figs 3 and 4) and inter-operator reproducibility (Fig 5).

Fig 3. Repeatability assessment for operator 1 (Bland-Altman plot).

Fig 4. Repeatability assessment for operator 2 (Bland-Altman plot).

Fig 5. Good agreement of 15 measurements for each of the 80 mandibles, between the two evaluators (Bland-Altman test).

In addition, agreement was obtained for the count of mandibular angle exostoses with excellent reproducibility (Weighted Cohen's Kappa coefficient = 0.94 for the right side and 0.96 for the left side).

Sample analysis

The characteristics of the 15 parameters recorded for the 80 mandibles in the sample are shown in Table 1.

Table 1. Descriptive statistics for the overall sample.

ROI	Minimum (mm)	Maximum (mm)	Mean (mm)	Standard deviation (mm)	Missing (number percents)	data and
Chin Height	16,80	39,53	29,05	4,25	1 (1,25%)	
Corpus Height	14,11	38,88	28,61	4,49	0 (0%)	
Corpus Width	7,79	15,70	11,30	1,64	0 (0%)	
Bigonial Breadth	81,38	121,14	99,21	8,07	11 (13,75%)	
Bicondylar Breadth	102,70	130,90	118,80	6,29	30 (37,5%)	
Minimum Ramus Width	23,71	41,66	31,72	3,75	0 (0%)	
Maximum Ramus Height	50,75	74,25	62,18	5,33	1 (1,25%)	
Corpus Length	63,00	85,00	73,32	4,85	0 (0%)	
Mandibular Angle	17,00	53,50	33,55	7,18	0 (0%)	
Maximum width of Right Condyle	5,17	13,46	8,67	1,34	15 (18,75%)	
Maximum Length of Right Condyle	15,36	24,35	20,54	2,10	20 (25%)	
Maximum Width of Left Condyle	5,84	12,05	8,68	1,21	14 (17,5%)	
Maximum Length of Left Condyle	16,60	23,73	20,34	1,76	16 (20%)	
Height of Right Coronoid Process	9,06	26,53	17,73	3,53	18 (22,5%)	
Height of Left Coronoid Process	9,03	26,28	17,37	3,57	14 (17,5%)	

ROI: Region Of Interest

The conditions for the application of Welch's t-test were checked for each group using an F-test for equality of variance between the two groups, and the normality of the distribution was checked using the Q-Q plot graphical method.

The statistical analysis of the overall sample using Welch's t-test, to investigate correlations between the presence of bony exostoses at the mandibular angle and significant dimensional variation in the 15 mandibular parameters investigated, is presented in Table 2.

Table 2. Statistical analysis of the mandibular measurements of the whole sample according to number of exostoses.

ROI	Group 1 mean ±SD (mm)	Group 2 mean ±SD (mm)	Welch Two Sample t-test <i>p-value</i>
Chin Height	28.45±4.01	29.74±4.46	0,07
Corpus Height	28.66±4.25	28.55±4.79	0,40
Corpus Width	11.33±1.76	11.27±1.51	0,87
Bigonial Breadth	94.88±7.40	103.17±6.53	0,0000003139**
Bicondylar Breadth	116.60±6.19	120.70±5.84	0,04471*
Minimum Ramus Width	31.71±4.16	31.73±3.29	0,50
Maximum Ramus Height	60.99±5.79	63.52±4.44	0,0347*
Corpus Length	72.68±5.51	74.02±3.94	0,21
Mandibular Angle	32.87±6.85	34.31±7.55	0,62
Maximum width of Right Condyle	8.49±1.48	8.86±1.17	0,34
Maximum Length of Right Condyle	20.21±2.02	20.89±2.16	0,42
Maximum Width of Left Condyle	8.53±1.20	8.83±1.21	0,21
Maximum Length of Left Condyle	19.65±1.68	21.03±1.58	0,04345*
Height of Right Coronoid Process	16.55±3.76	19.00±2.82	0,00528**
Height of Left Coronoid Process	16.44±3.79	18.41±3.03	0,007831**

ROI: Region Of Interest. SD: Standard Deviation. p: significance level; *significance level, $p < 0.05$;

**significance level, $p < 0.001$

A statistically significant difference was demonstrated between group 1 (number of exostoses ≤ 1) and group 2 (number of exostoses ≥ 2) for the following parameters: distance between mandibular angles, bicondylar width, ramus height, left condyle length, right and left coronoid process height. For each of these parameters, values were higher in group 2 than in group 1.

Discussion

This study aimed to assess the presence of morphological changes in the mandible associated with the presence of bony exostoses at the mandibular angles. It was carried out on subjects recovered by archaeological excavation from two cemeteries located in the same geographical area (the city of Marseille and surrounding area, in southern France), in two series situated in the modern and contemporary historical periods.

The selection of these series was motivated by the desire to carry out a diachronic study on archaeological series presenting comparable geographical and environmental conditions, to limit the impact of extrinsic factors likely to have affected the state of health of the subjects buried in these cemeteries.

The archaeological series approach in itself denies researchers access to information relating to the behaviours adopted by subjects during their lifetime. However, this approach allows researchers to apprehend and measure distances directly, and even to evaluate volumes, freeing them from the potential bias in reconstructing cross-sections and volumes that is inherent in radiological techniques. The latter are particularly useful for assessing internal bone parameters such as bone density, as they avoid the need to destroy tissue to collect data; these two approaches therefore appear to be complementary for study of the mandible. Data collection was closely impacted by the state of preservation of subjects and considerable variability was noted both in the number of bone pieces found during excavation and in their state of preservation in situ and then in the laboratory. Thus, while archaeological series provide access to collections of bone remains, the authors had to work with missing data, all of which represent a source of potential bias, as not all mandibles present an optimal level of preservation. Furthermore, in order not to introduce any additional bias, teeth, which are often used in the archaeological study of mandibles, were excluded from data collection, as mandibles were often found without all teeth in situ: the collection of parameters such as wear or carious lesions appeared too random to be exploitable for statistical purposes.

The 80 mandibles were divided into two groups according to the number of mandibular exostoses counted at both mandibular angles. It was decided that a subject with a unilateral exostosis associated with the absence of an exostosis at the contralateral angle would be grouped with individuals with no exostosis at either angle, as this isolated exostosis alone could not reflect overactivity of the masticatory muscles. Thus, the presence of at least two exostoses was chosen as more likely to distinguish a parafunctional increase in mandibular activity from ordinary manducatory activity. [20,21].

The mandibular characteristics associated with the presence of exostoses at the mandibular angle have been studied in the literature. Indeed, several studies [9,20,22] associate the presence of mandibular exostoses with the expression of a parafunctional activity called bruxism, which reflects intense activity of the muscles of the manducatory apparatus. Other articles focus on the development of mandibular tori, which are oral exostoses located on the medial aspect of the mandibular arch. Research has also shown that signs of parafunctional activity are associated with the presence of mandibular tori [23].

The impact on the mandible of these parafunctional muscular activities associated with bruxism has been the subject of various published studies, based mainly on two-dimensional medical imaging, and involving the analysis of panoramic radiographs. Morphological changes in the mandible have been described, which sometimes contradict the data collected in this study. As a reminder, the study of archaeological collections has highlighted several morphological changes in the mandible, relating to parameters such as the distance between the mandibular angles, bicondylar width, ramus height, left condyle length, and right and left coronoid process height. The values of all these parameters were increased in subjects with multiple exostoses at the mandibular angles. These changes affected several anatomical regions of the mandible.

Various results have been presented for the condylar region of the mandible: the present study showed an increase in the length of the left mandibular condyle; one study [24] found no significant difference; several others [25–27] showed a reduction in condylar dimensions. This result should be treated with caution, as it was demonstrated for the left condyle only. Measurements of right condyle length, as well as maximum condyle widths on both sides, showed no statistically significant difference

between the two groups. Furthermore, many factors have been described in the literature as inducing variations in mandibular condyle shape, such as age, gender, facial typology, and intermaxillary dental relationships [28,29]. This ability to remodel the shape of the condyle reflects its functional adaptation throughout an individual's life, and the resulting modifications are often described as asymmetrical.

A bilateral increase in dimensions was found in the coronoid process region in this study. This is corroborated by the study of Cezairli *and al.* [30]; Padmaja Satheeswarakumar *et al.* [25] observed coronoid process measurements in bruxers that were significantly smaller on the right but larger on the left. A possible explanation for this size increase could relate to the insertion of the temporalis muscle and the deep fascicle of the masseter muscle on the lateral aspect of the coronoid processes: sustained muscular activity could explain the higher level of bone development found in patients with multiple exostoses.

Finally, this study reported an increased distance between the mandibular angles and between the lateral poles of the condyles in subjects with multiple exostoses compared to the other group. Although these measurements were not collected in the medical imaging studies, it is possible to advance an explanatory hypothesis based on knowledge of mandibular biomechanics. Indeed, Van Eijden [31] reported that during contraction of the elevator muscles, the mandible undergoes lateral flexion in the transverse direction, resulting in lateral torsion of the lower mandibular border. It thus seems possible to suggest that repetition of these muscle contractions over time has resulted in a widening of the intercondylar distance, and consequently an increased intercondylar distance due to the anatomical configuration of the mandible.

Conclusion

This study presents an original methodology for studying anatomical variations of the mandible in the context of parafunctional activity, highlighting certain mandibular modifications. The presence of bilateral mandibular exostoses was correlated with higher values for the distance between mandibular angles, bicondylar width, ramus height, left condylar length, and right and left coronoid process height.

The variations observed corroborated certain results present in the international literature. In addition, we did not investigate certain characteristics, such as bone density, by observation of trabecular bone, as study of the collections required the use of non-invasive methods. The use of imaging examinations could represent a potentially valuable research approach, whether applied to archaeological series or patient cohorts. Mandibular bone density has been analysed on panoramic X-rays, and the use of three-dimensional imaging, such as CBCT, which avoids the reconstruction bias and distortions of two-dimensional examinations, would appear to be a sensible option for future research, both in terms of bone density and morphological variations.

The impact of parafunctional behaviours such as bruxism on the mandible therefore has many anatomical expressions. The considerable variability of results found in the literature shows that more studies are needed to reach a consensus on the impact of parafunctional activities on the mandible.

References

- [1] Duncan RL, Turner CH. Mechanotransduction and the functional response of bone to mechanical strain. *Calcif Tissue Int* 1995;57:344–58. <https://doi.org/10.1007/BF00302070>.
- [2] Bassett JHD, Williams GR. Role of Thyroid Hormones in Skeletal Development and Bone Maintenance. *Endocr Rev* 2016;37:135–87. <https://doi.org/10.1210/er.2015-1106>.
- [3] Buvinic S, Balanta-Melo J, Kupczik K, Vásquez W, Beato C, Toro-Ibacache V. Muscle-Bone Crosstalk in the Masticatory System: From Biomechanical to Molecular Interactions. *Front Endocrinol* 2020;11:606947. <https://doi.org/10.3389/fendo.2020.606947>.
- [4] Choi AH, Conway RC, Taraschi V, Ben-Nissan B. Biomechanics and functional distortion of the human mandible. *J Investig Clin Dent* 2015;6:241–51. <https://doi.org/10.1111/jicd.12112>.
- [5] Wolff JD. *Das Gesetz der Transformation der Knochen*, Berlin: Verlag von Auguste Hirschwald, 1892.
- [6] Frost HM. A 2003 update of bone physiology and Wolff's Law for clinicians. *Angle Orthod* 2004;74:3–15. [https://doi.org/10.1043/0003-3219\(2004\)074<0003:AUOBPA>2.0.CO;2](https://doi.org/10.1043/0003-3219(2004)074<0003:AUOBPA>2.0.CO;2).

- [7] Brotto M, Bonewald L. Bone and muscle: Interactions beyond mechanical. *Bone* 2015;80:109–14.
<https://doi.org/10.1016/j.bone.2015.02.010>.
- [8] Torres-del-Pliego E, Vilaplana L, Güerri-Fernández R, Díez-Pérez A. Measuring bone quality. *Curr Rheumatol Rep* 2013;15:373. <https://doi.org/10.1007/s11926-013-0373-8>.
- [9] Casazza E, Ballester B, Philip-Alliez C, Raskin A. Evaluation of mandibular bone density in bruxers: the value of panoramic radiographs. *Oral Radiol* 2023;39:117–24.
<https://doi.org/10.1007/s11282-022-00612-3>.
- [10] Kebede B, Megersa S. Idiopathic masseter muscle hypertrophy. *Ethiop J Health Sci* 2011;21:209–12.
- [11] Antunes JJ, Almeida SA, Monteiro RMP de C, Martins AM. Idiopathic masseter muscle hypertrophy: a case report. *Einstein* 2019;17.
https://doi.org/10.31744/einstein_journal/2019AI4506.
- [12] Manfredini D, Ahlberg J, Aarab G, Bracci A, Durham J, Emodi-Perlman A, et al. The development of the Standardised Tool for the Assessment of Bruxism (STAB): An international road map. *J Oral Rehabil* 2022. <https://doi.org/10.1111/joor.13380>.
- [13] Richier A, Weydert N. Bouches-du-Rhône, Marseille, prolongement de la ligne 2 du métro de Bougainville vers Capitaine Gèze - 72 avenue Félix Zoccola. Ancien cimetière des Crottes. Rapport final d’opération préventive. Inrap Méditerranée, SRA PACA. Nîmes: 2016.
- [14] Perrin M. État sanitaire entre Ancien Régime et révolution industrielle: Étude paléoépidémiologique de deux populations provençales. *BAR International Series*. Oxford: 2021.
- [15] Bruzek J. A method for visual determination of sex, using the human hip bone. *American Journal of Physical Anthropology*. 2002;117:157-168.
- [16] Murail P, Brůžek J, Houët F, Cunha E. DSP: A tool for probabilistic sex diagnosis using worldwide variability in hip-bone measurements. *Bull Mém Société D’Anthropologie Paris BMSAP* 2005;17:167–76. <https://doi.org/10.4000/bmsap.1157>.
- [17] Richier A. Bouches-du-Rhône, La Ciotat. Carré Saint-Jacques: L’îlot Saint-Jacques, du vignoble champêtre au cimetière paroissial. Rapport final d’opération préventive. Inrap Méditerranée, SRA PACA. Nîmes: 2011.

- [18]Langley NR, Jantz LM, Ousley SD, Jantz RL, Milner G. Data collection procedures for forensic skeletal material 2.0. Knoxville, TN: Forensic Anthropology Center, Department of Anthropology, University of Tennessee; 2016. p. 107.
- [19]Buikstra J, Ubelaker D. Standards for Data Collection From Human Skeletal Remains. Arkansas Archeological Survey Research Series. Fayette-Ville: 1994.
- [20]Türp JC, Simonek M, Dagassan D. Bone apposition at the mandibular angles as a radiological sign of bruxism: a retrospective study. BMC Oral Health 2021;21:537. <https://doi.org/10.1186/s12903-021-01804-9>.
- [21]Casazza E, Ballester B, Siaud B, Philip-Alliez C, Raskin A. Relationship between bruxism and mandibular bone modifications based on medical imaging: a scoping review. BMC Oral Health 2023;23:483. <https://doi.org/10.1186/s12903-023-03209-2>.
- [22]Isman O. Evaluation of jaw bone density and morphology in bruxers using panoramic radiography. J Dent Sci 2021;16:676–81. <https://doi.org/10.1016/j.jds.2020.09.008>.
- [23]Cortes ARG, Jin Z, Morrison MD, Arita ES, Song J, Tamimi F. Mandibular Tori Are Associated With Mechanical Stress and Mandibular Shape. J Oral Maxillofac Surg 2014;72:2115–25. <https://doi.org/10.1016/j.joms.2014.05.024>.
- [24]Eninanç İ, Yalçın Yeler D, Çınar Z. Investigation of mandibular fractal dimension on digital panoramic radiographs in bruxist individuals. Oral Surg Oral Med Oral Pathol Oral Radiol 2021;131:600–9. <https://doi.org/10.1016/j.oooo.2021.01.017>.
- [25]Padmaja Satheeswarakumar L, Elenjickal TJ, Ram SKM, Thangasamy K. Assessment of Mandibular Surface Area Changes in Bruxers Versus Controls on Panoramic Radiographic Images: A Case Control Study. Open Dent J 2018;12:753–61. <https://doi.org/10.2174/1745017901814010753>.
- [26]Gulec M, Tassoker M, Ozcan S, Orhan K. Evaluation of the mandibular trabecular bone in patients with bruxism using fractal analysis. Oral Radiol 2020. <https://doi.org/10.1007/s11282-020-00422-5>.

- [27] Serafim I, Rode S, Lopes S, Oliveira W, Pinho S, Silva E, et al. Impact of bruxism on craniomandibular morphology: A cone-beam computed tomographic study. *Cranio J Craniomandib Pract* 2022;1–11. <https://doi.org/10.1080/08869634.2022.2139334>.
- [28] Sheppard SM. Asymptomatic morphologic variations in the mandibular condyle-ramus region. *J Prosthet Dent* 1982;47:539–44. [https://doi.org/10.1016/0022-3913\(82\)90306-7](https://doi.org/10.1016/0022-3913(82)90306-7).
- [29] Cioffi I, van Ruijven LJ, Renders G a. P, Farella M, Michelotti A, van Eijden TMGJ. Regional variations in mineralization and strain distributions in the cortex of the human mandibular condyle. *Bone* 2007;41:1051–8. <https://doi.org/10.1016/j.bone.2007.08.033>.
- [30] Cezairli B, Torul D, Kahveci K. The association between bruxism and mandibular morphology: A cross-sectional study. *J Oral Health Oral Epidemiol* 2022;11:19–24. <https://doi.org/10.22122/johoe.2022.195434.1234>.
- [31] van Eijden TM. Biomechanics of the mandible. *Crit Rev Oral Biol Med Off Publ Am Assoc Oral Biol* 2000;11:123–36. <https://doi.org/10.1177/10454411000110010101>.

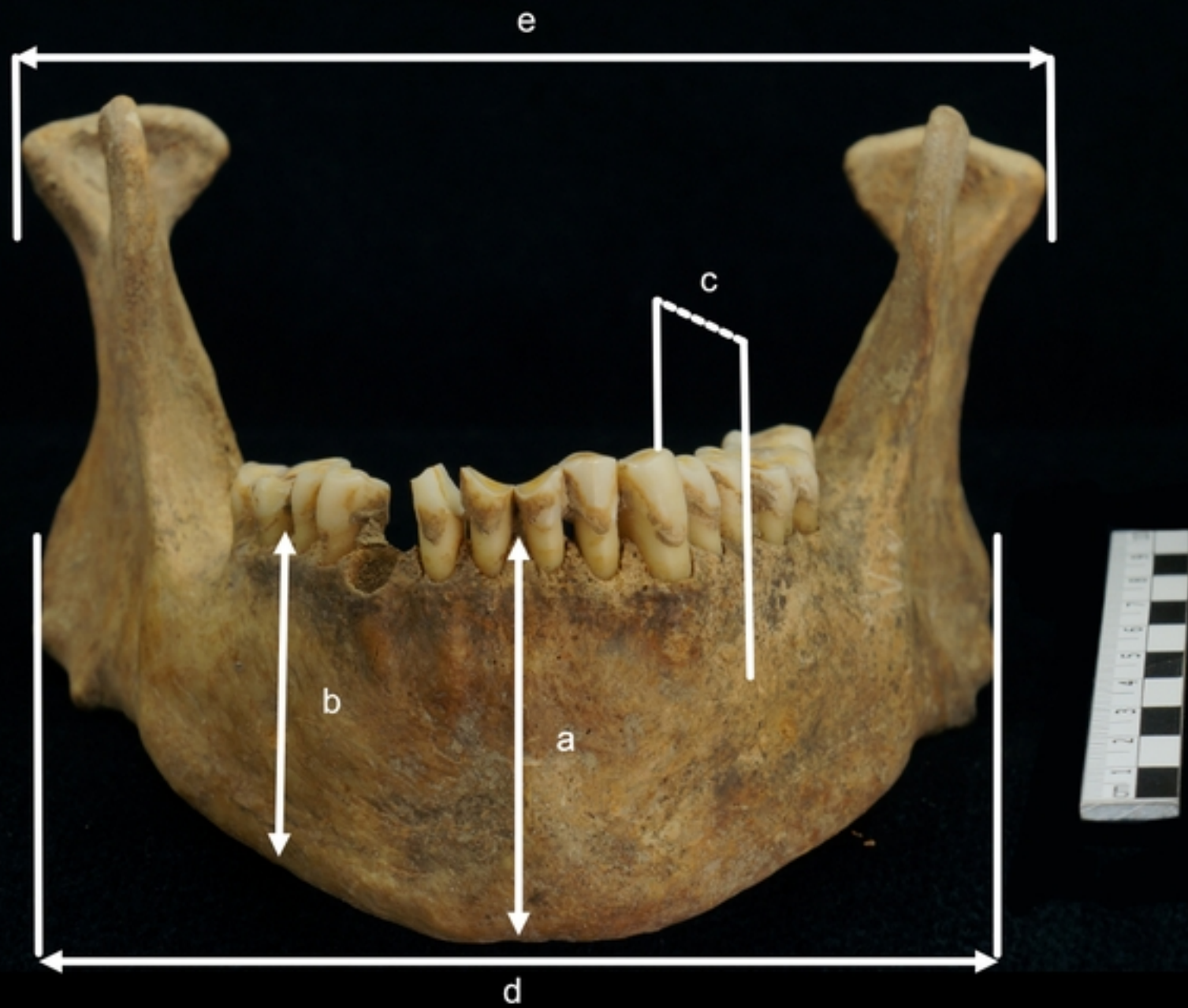

Fig 1a



Fig 1b

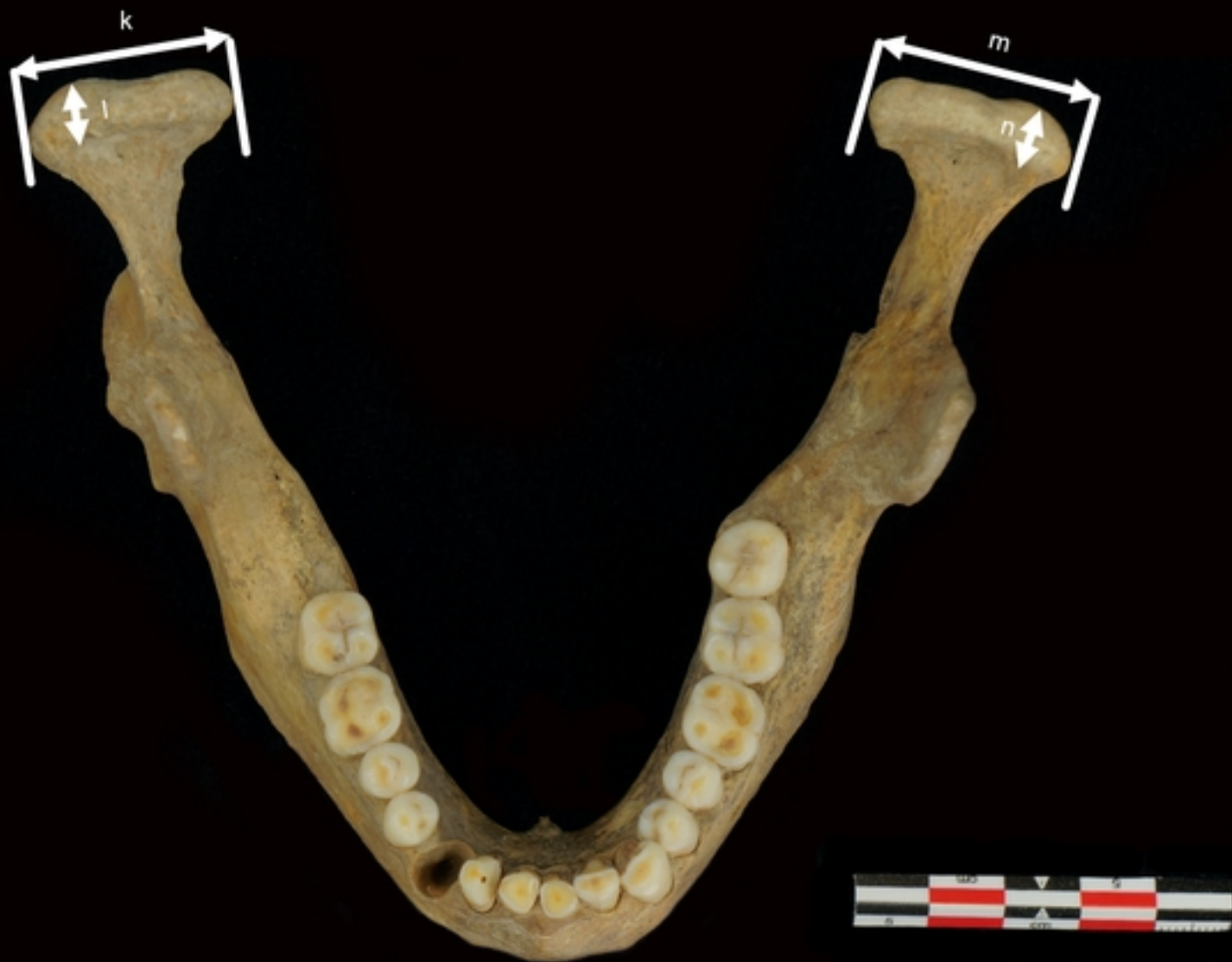

Fig 1c

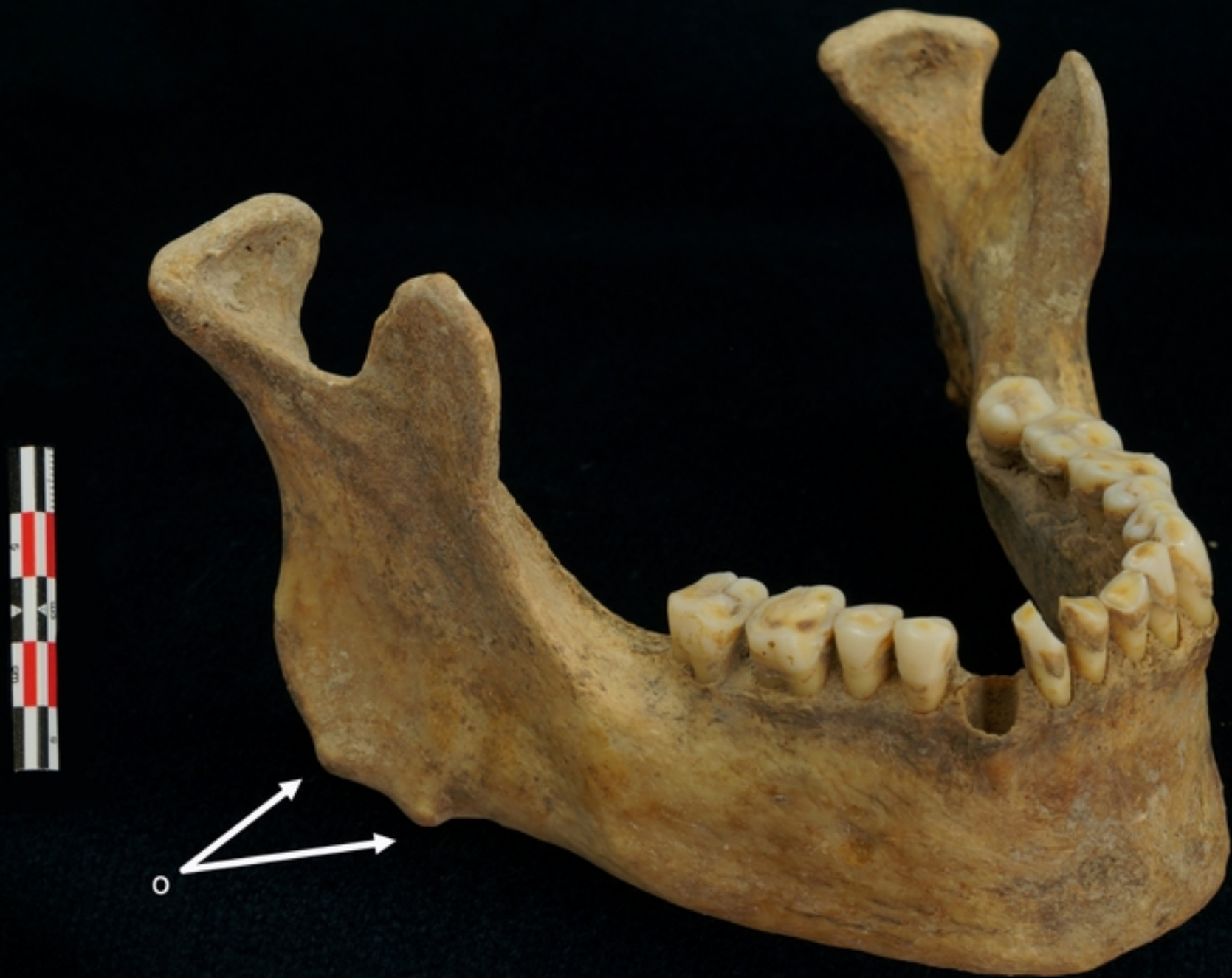

Fig 1d

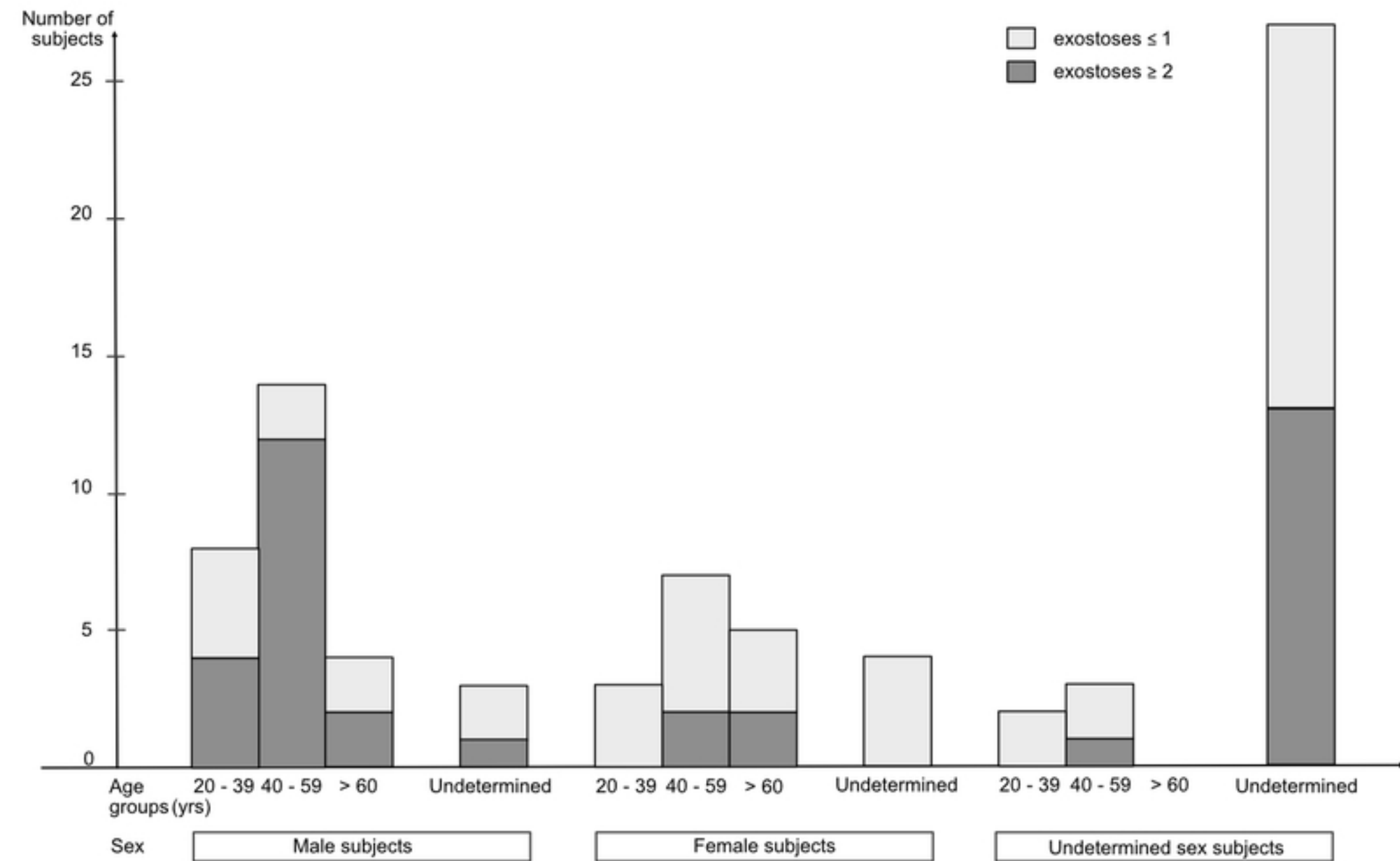
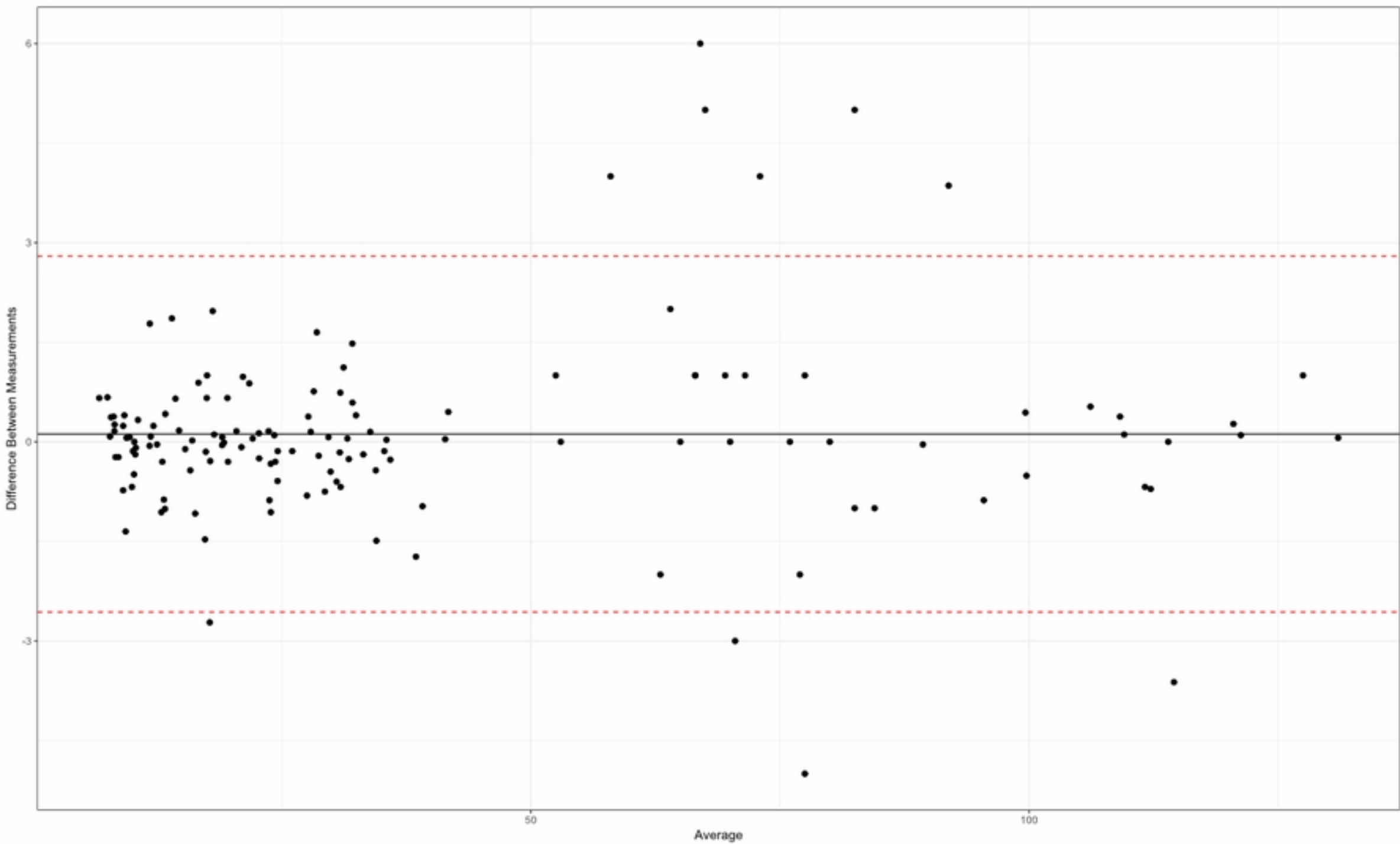


Fig 2



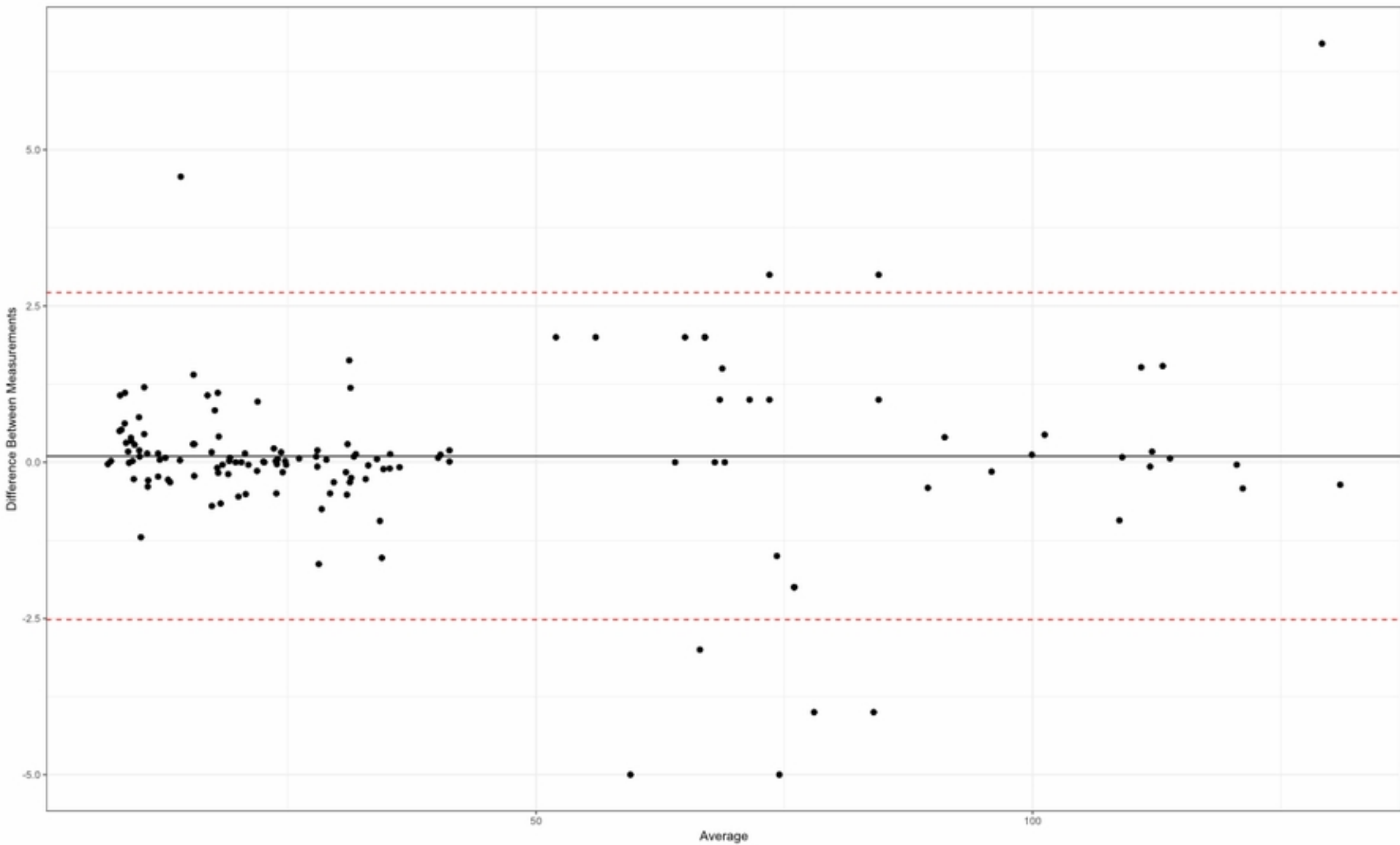


Fig 4

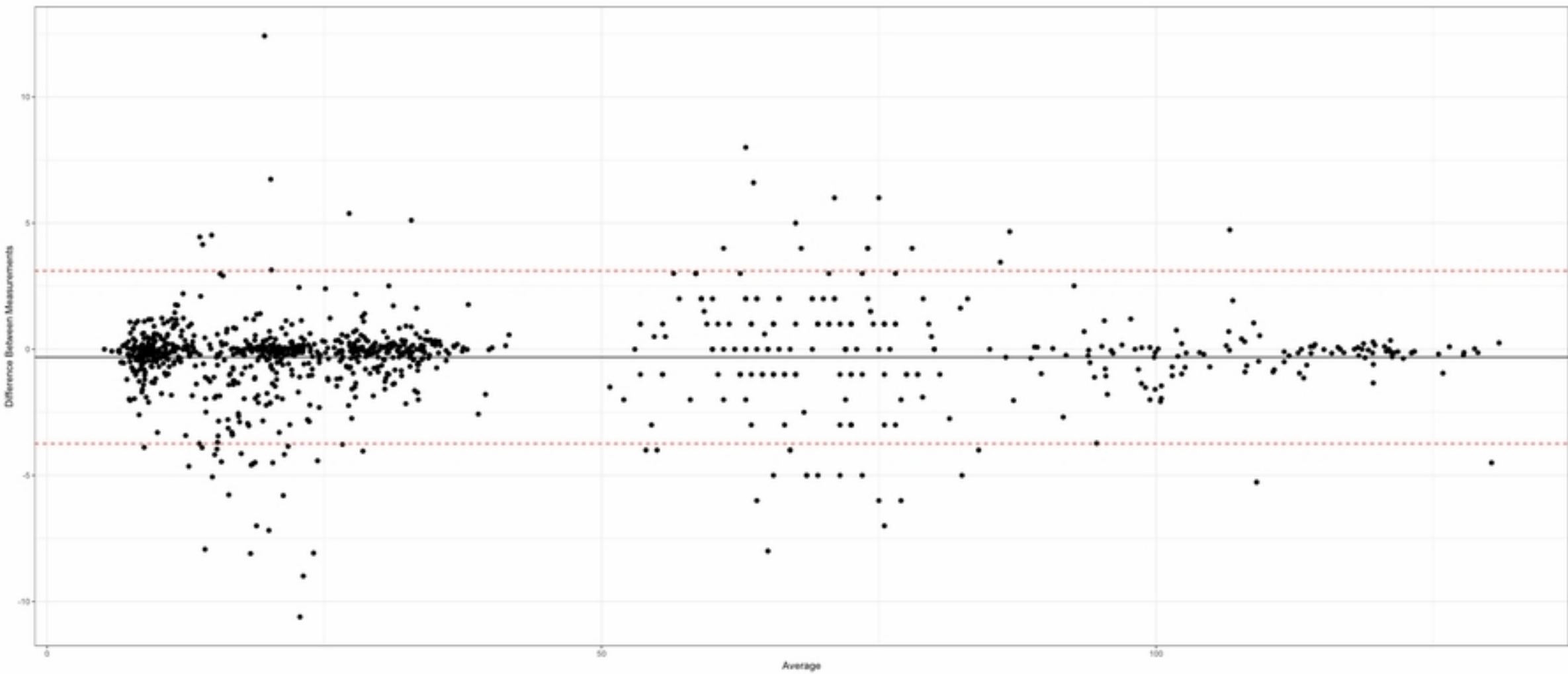


Fig 5