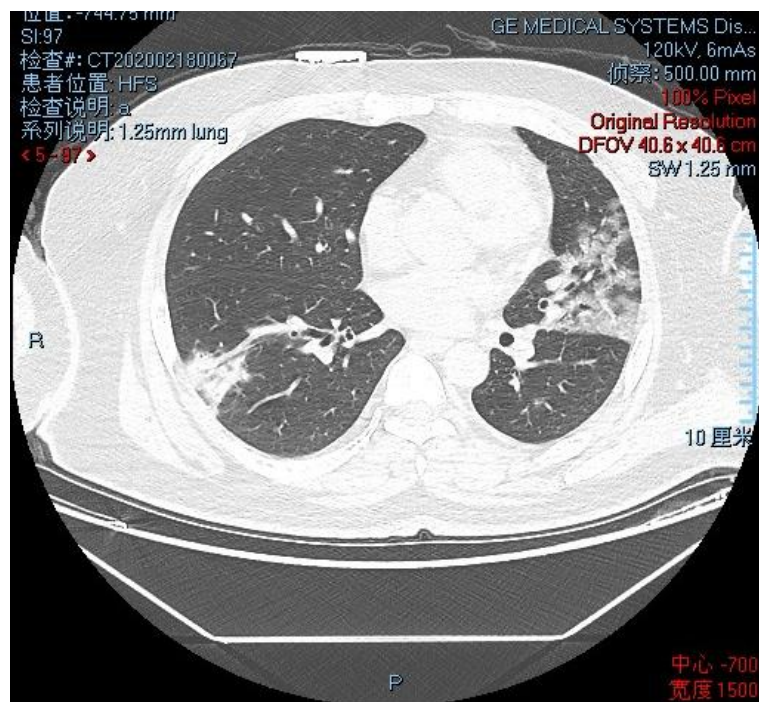
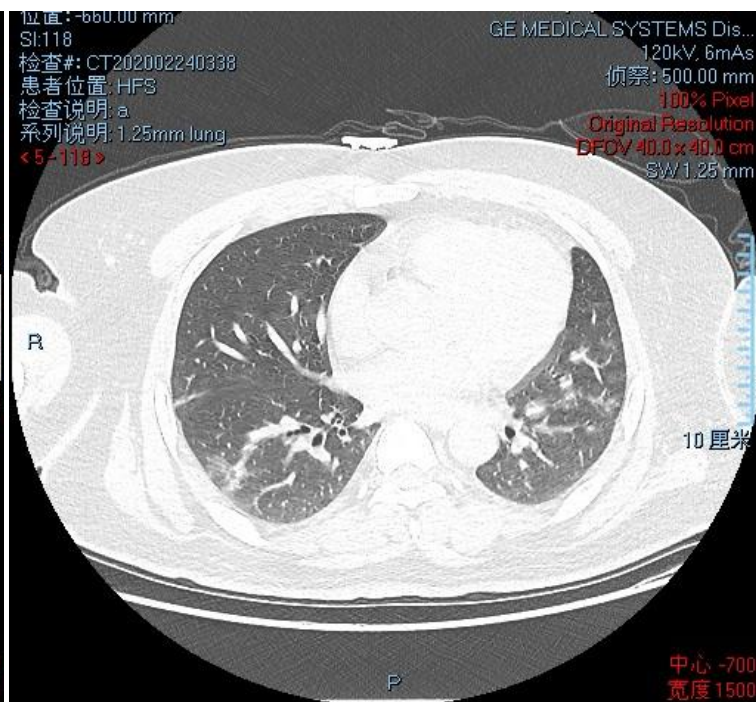


Figure S1. Computed Tomography (CT)-based radiographs for each included patient with COVID-19 in the $^{99\text{m}}\text{Tc}$ -MDP and control groups. For those who discharged during 7 days to 14 days, there is no CT radiograph at day 14.

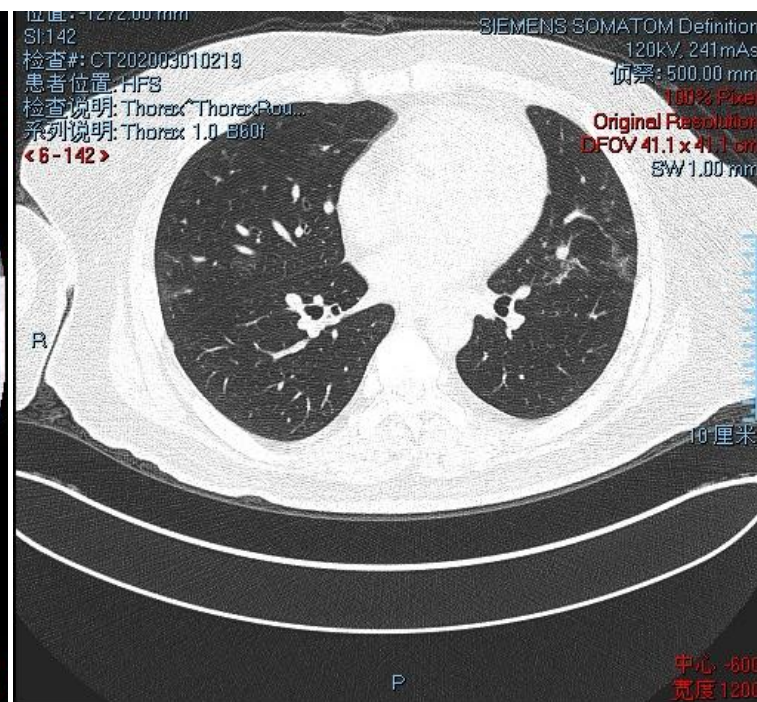
Patient 1 ^{99m}Tc -MDP group



At admission

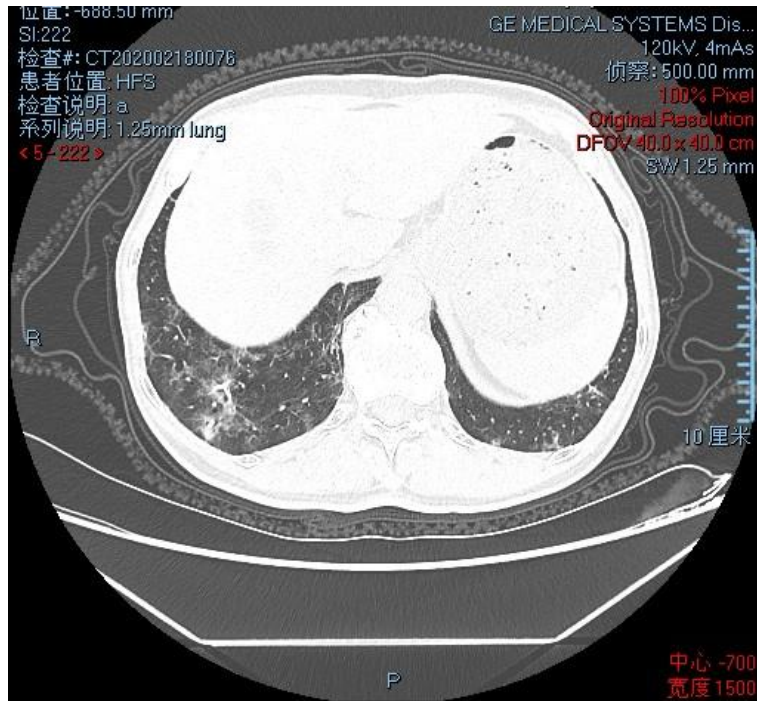


At 7 day

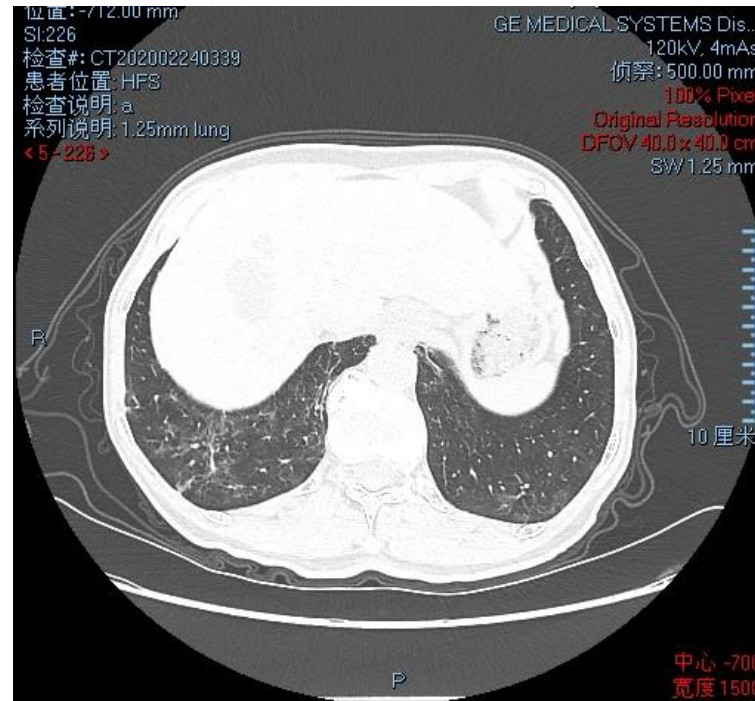


At 14 day

Patient 2 ^{99m}Tc -MDP group

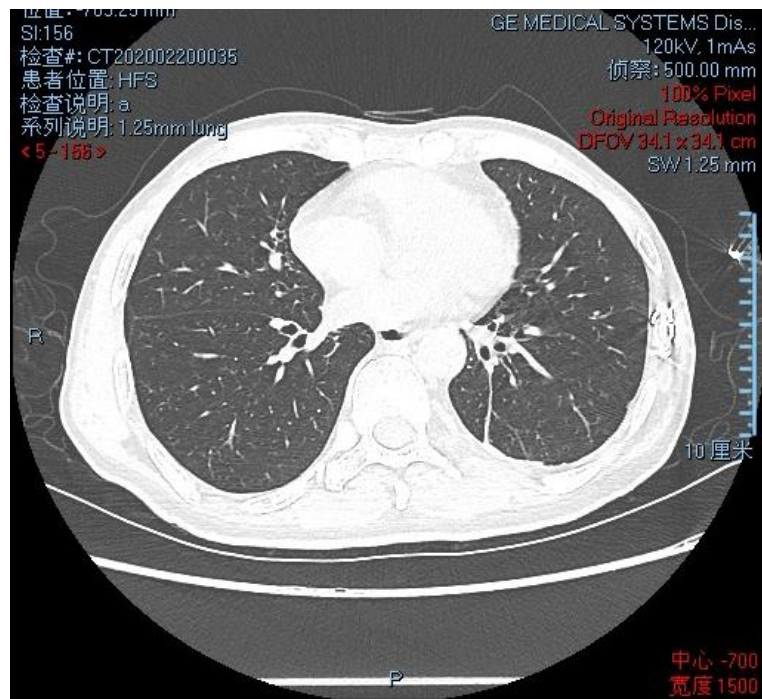


At admission

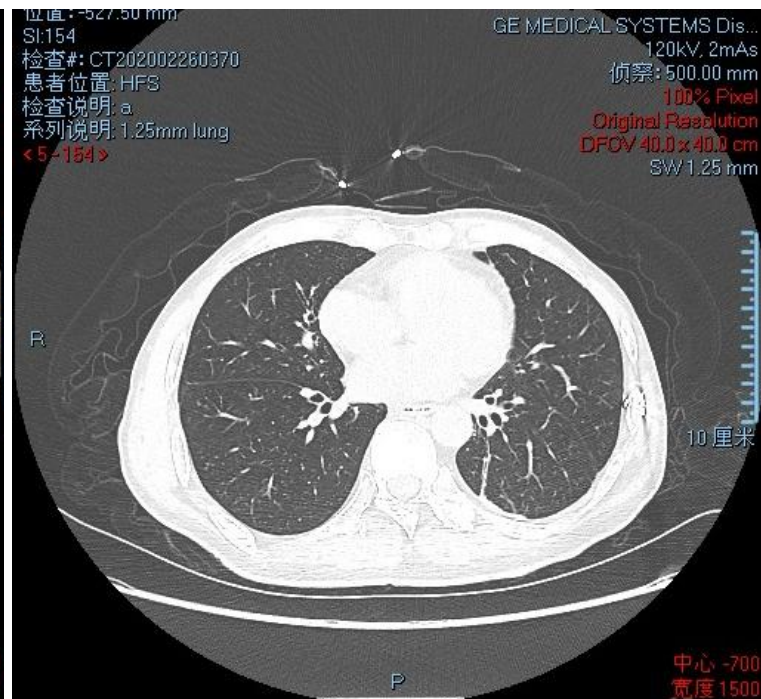


At 7 day

Patient 3 ^{99m}Tc -MDP group

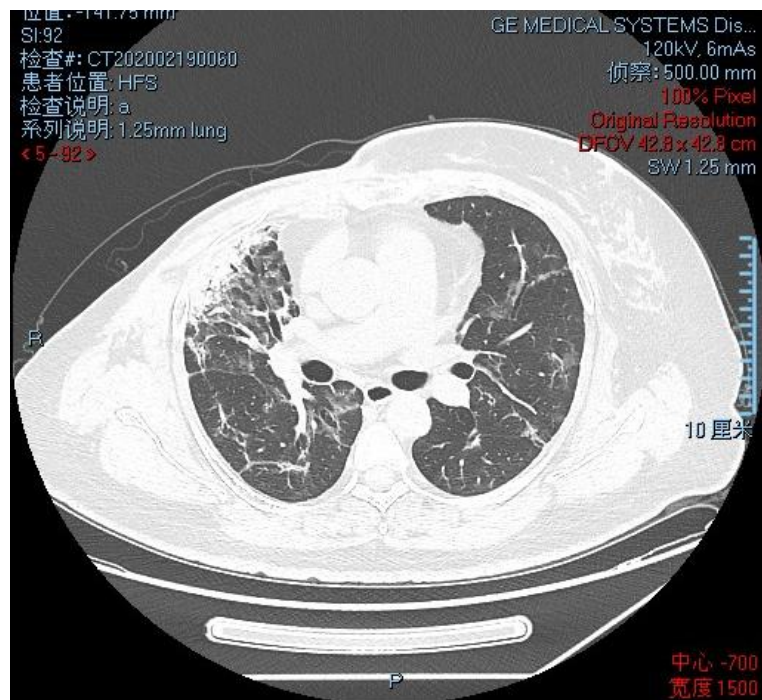


At admission

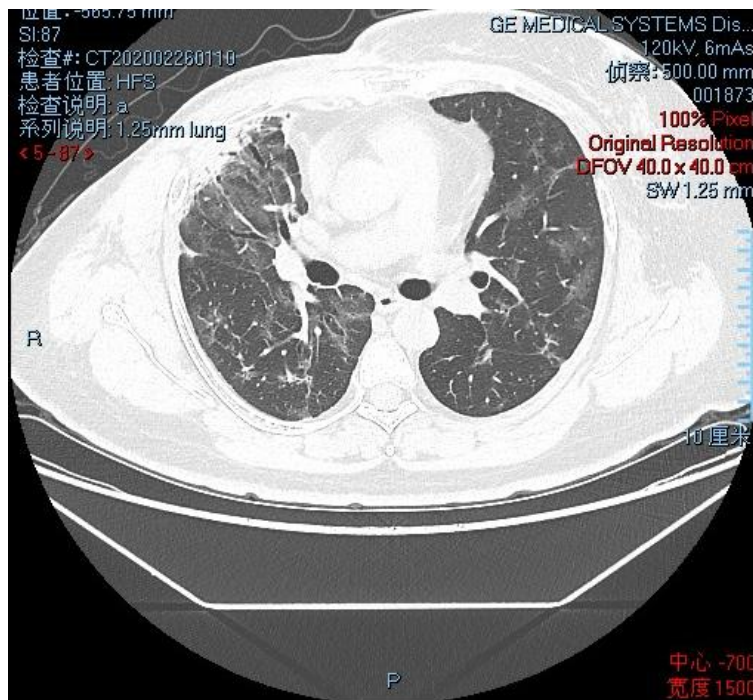


At 7 day

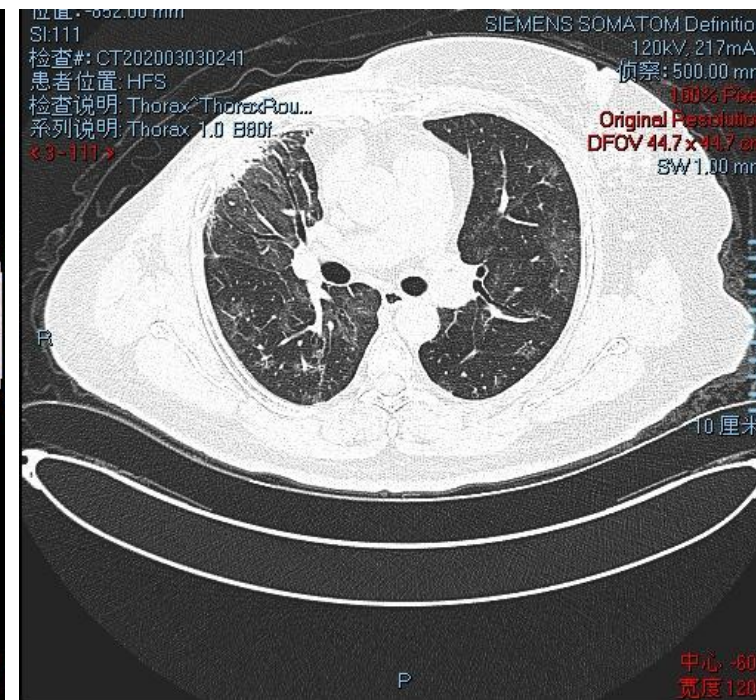
Patient 4 ^{99m}Tc -MDP group



At admission

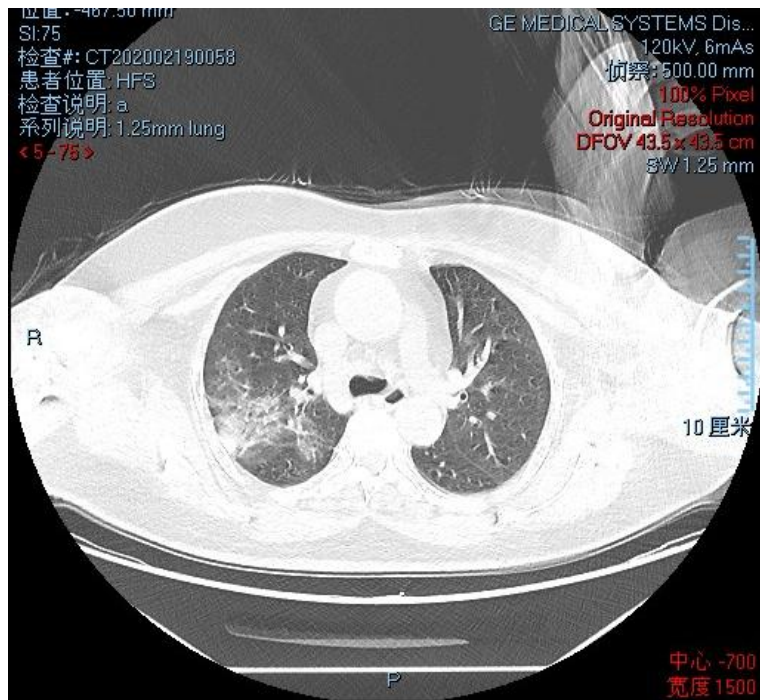


At 7 day

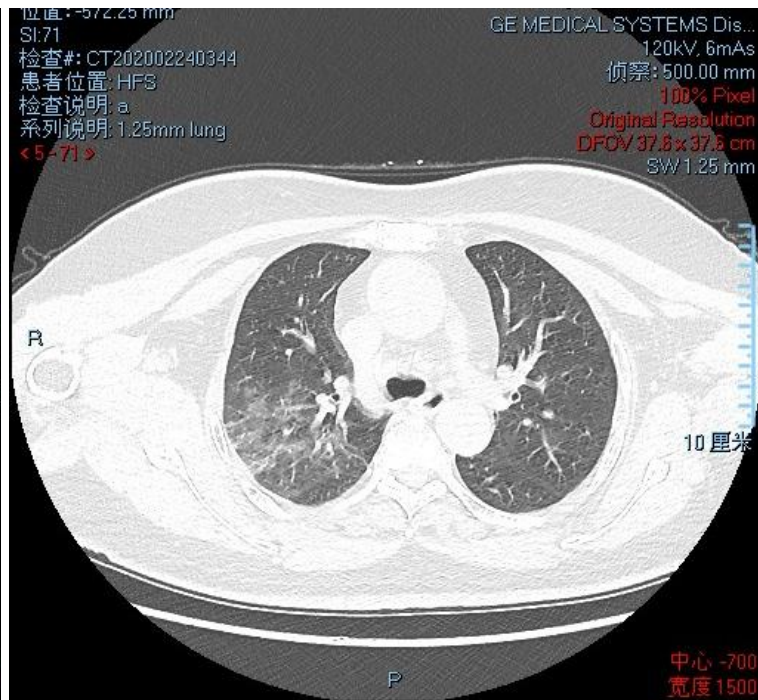


At 14 day

Patient 5 ^{99m}Tc -MDP group

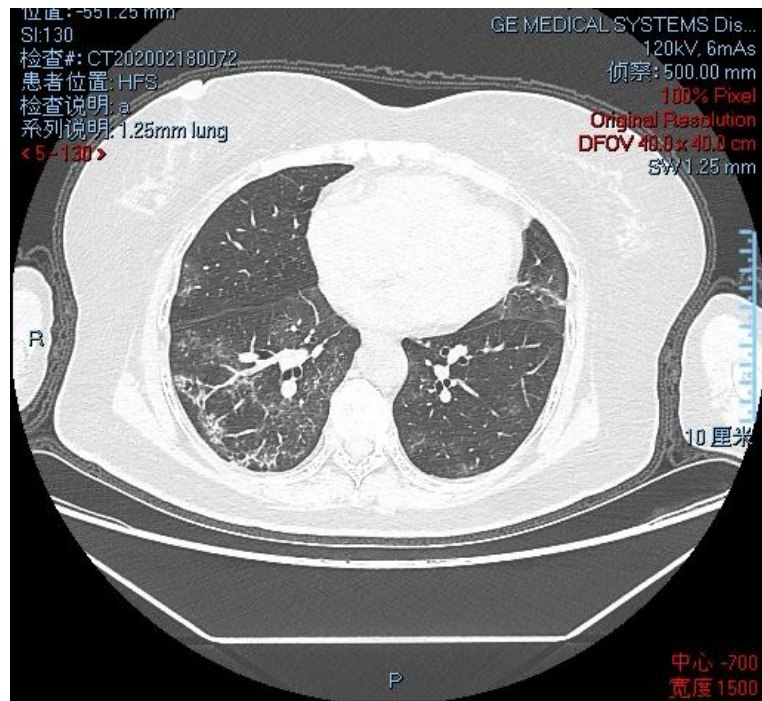


At admission

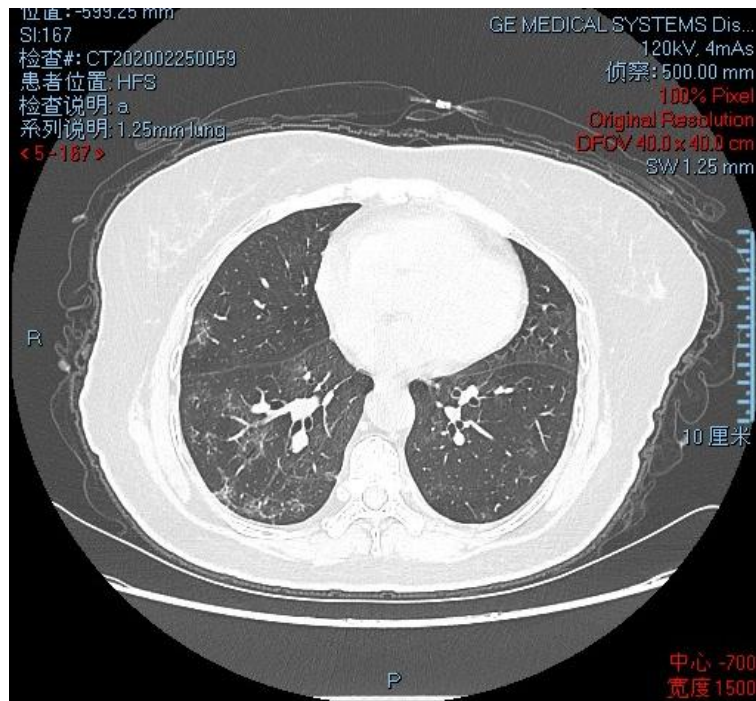


At 7 day

Patient 6 ^{99m}Tc -MDP group

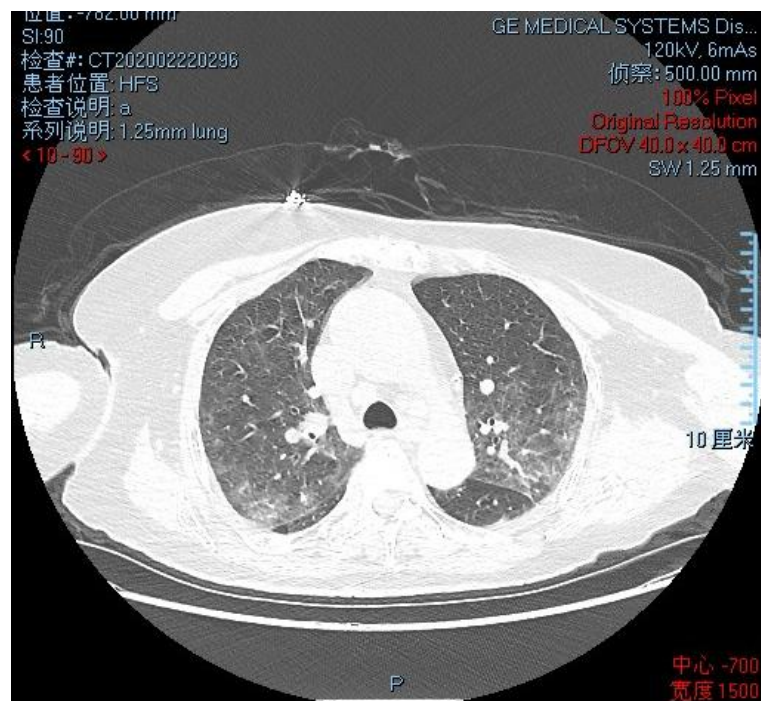


At admission

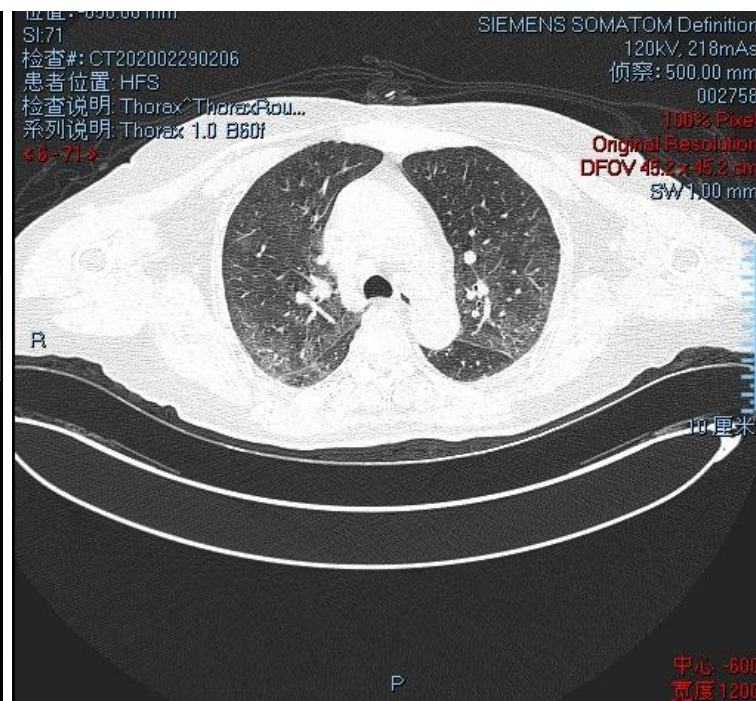


At 7 day

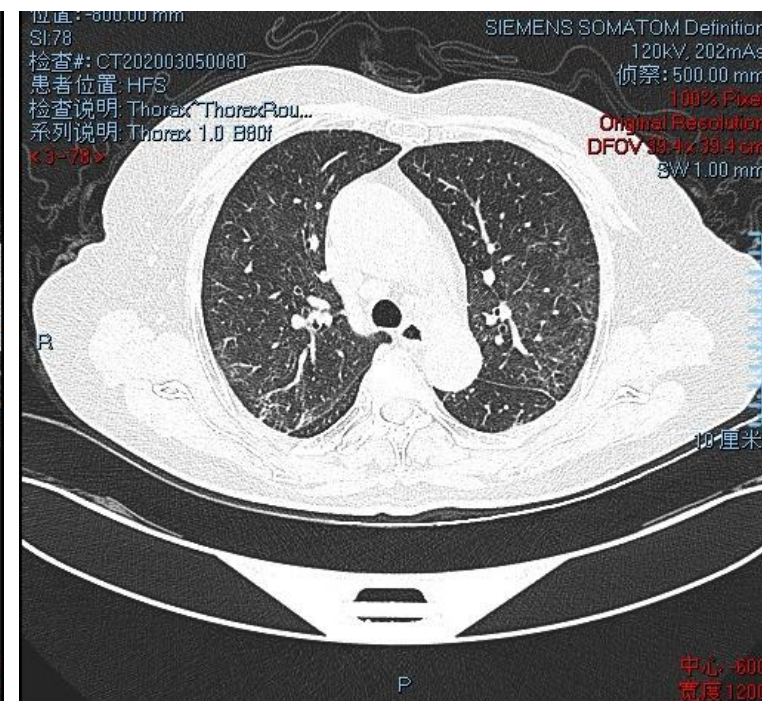
Patient 7 ^{99m}Tc -MDP group



At admission

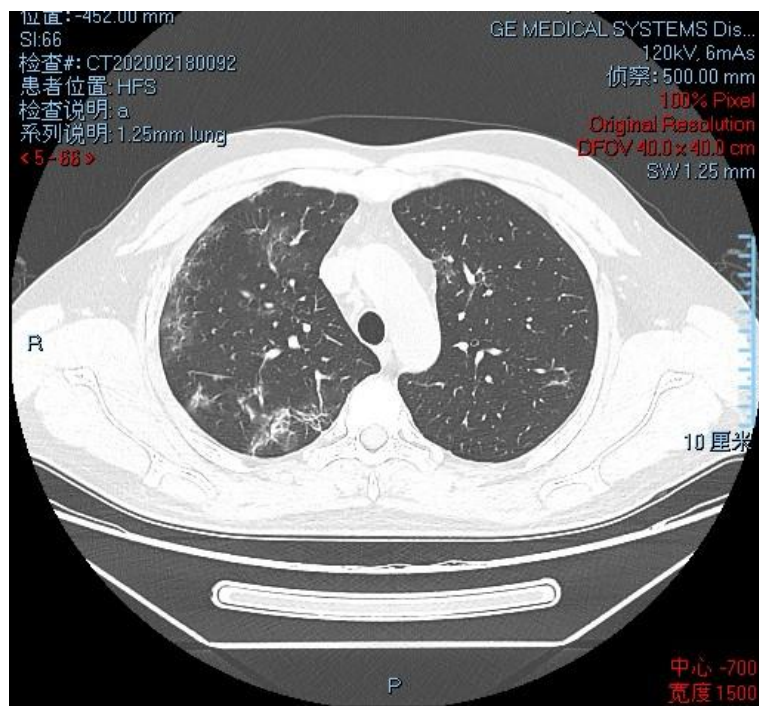


At 7 day

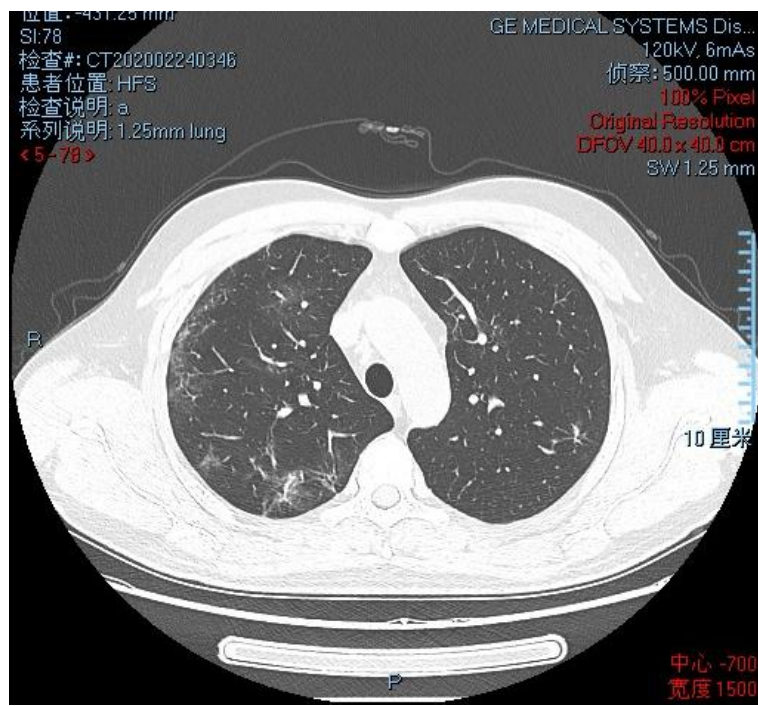


At 14 day

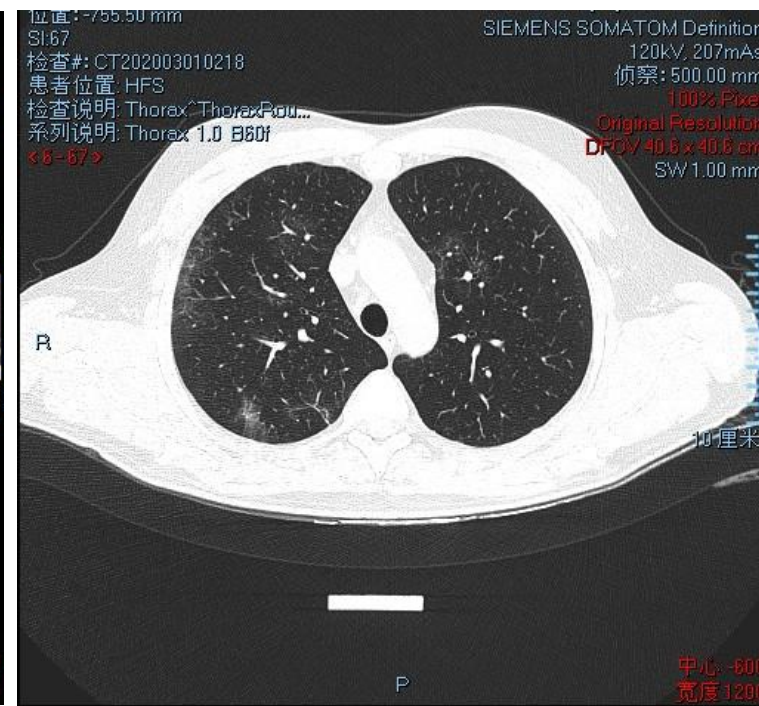
Patient 8 ^{99m}Tc -MDP group



At admission

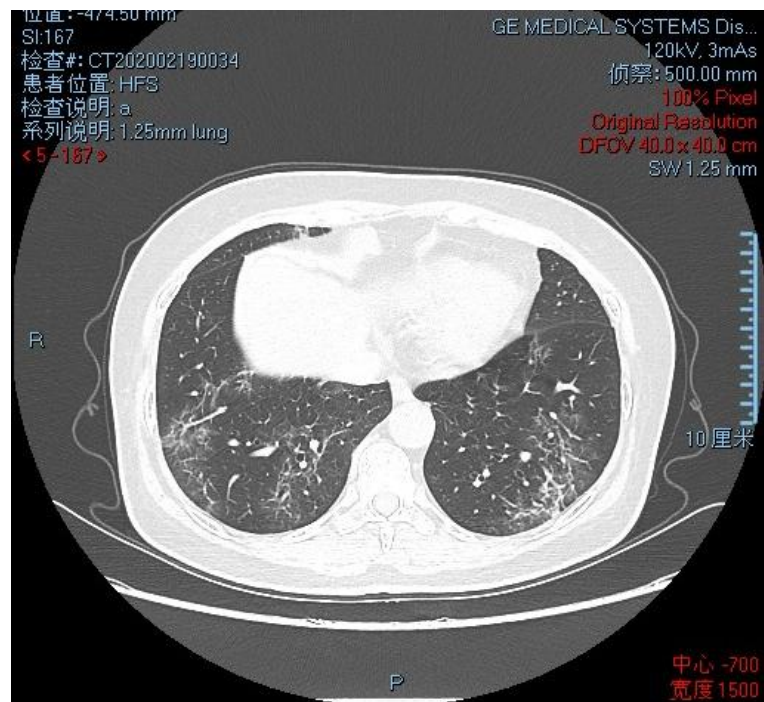


At 7 day

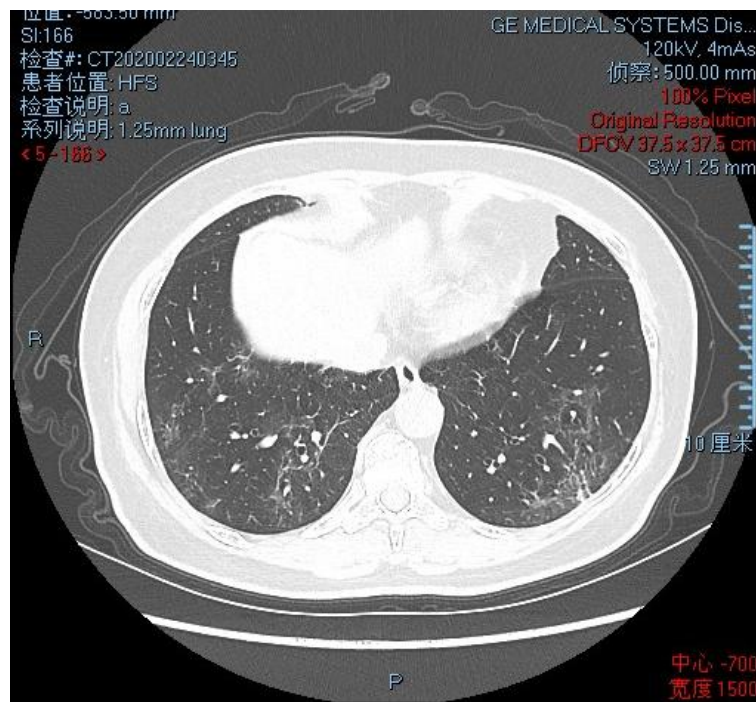


At 14 day

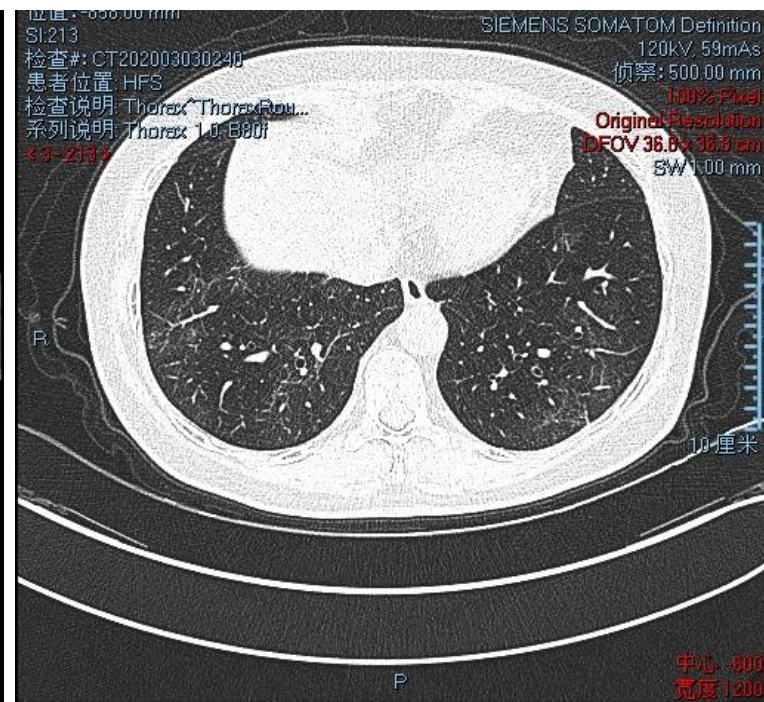
Patient 9 ^{99m}Tc -MDP group



At admission

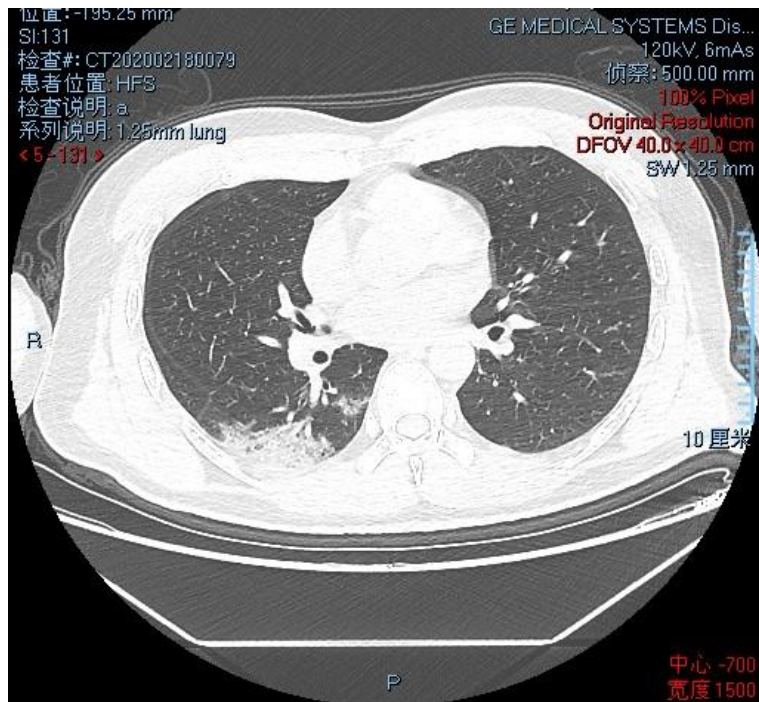


At 7 day

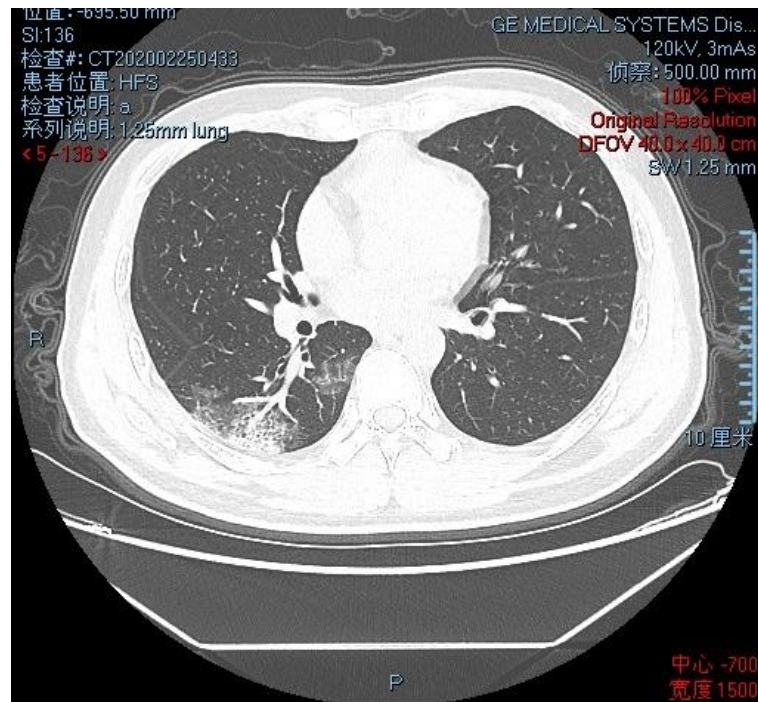


At 14 day

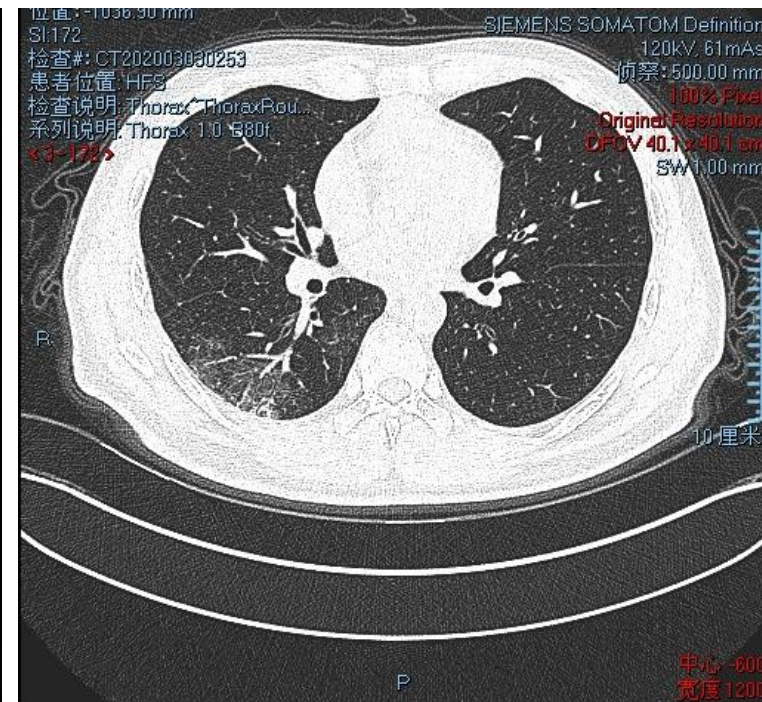
Patient 10 Control group



At admission

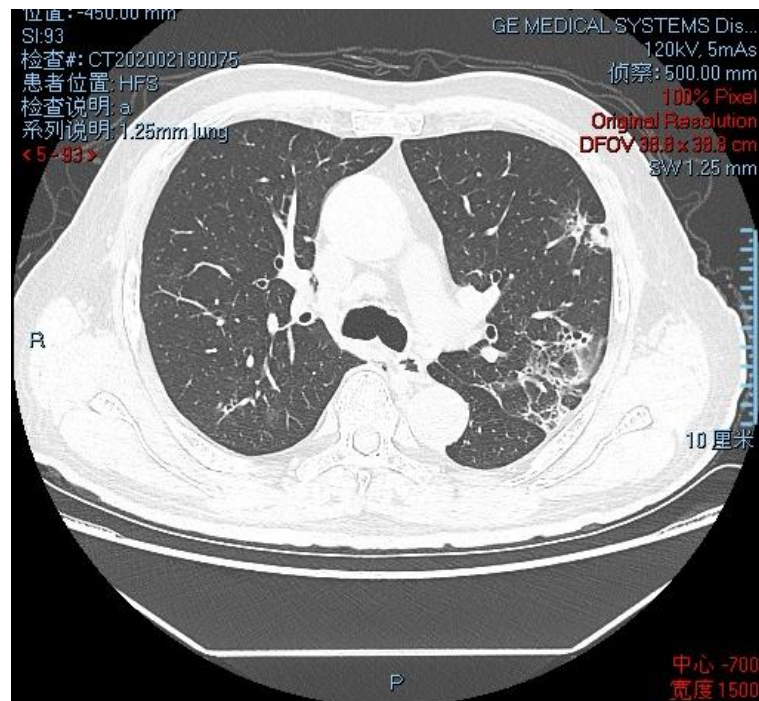


At 7 day

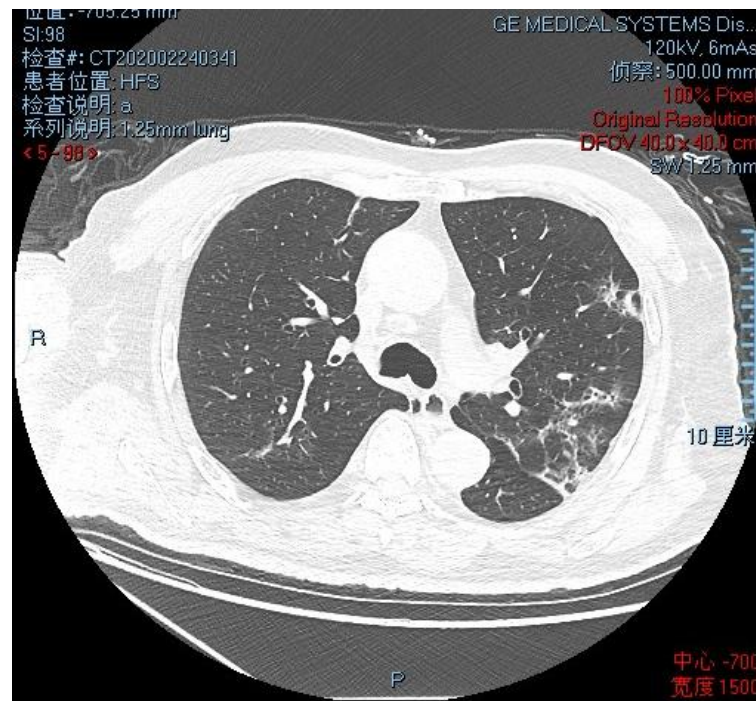


At 14 day

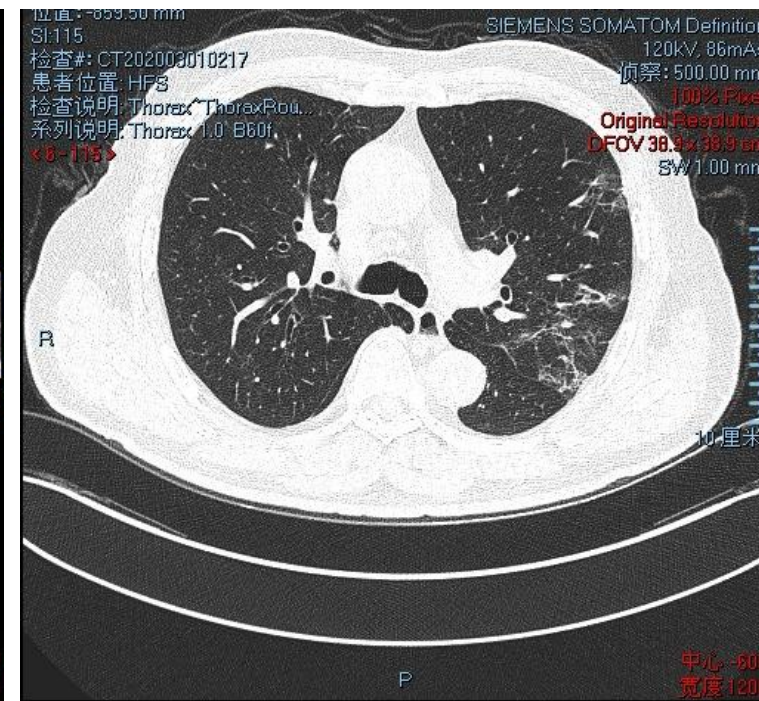
Patient 11 Control group



At admission

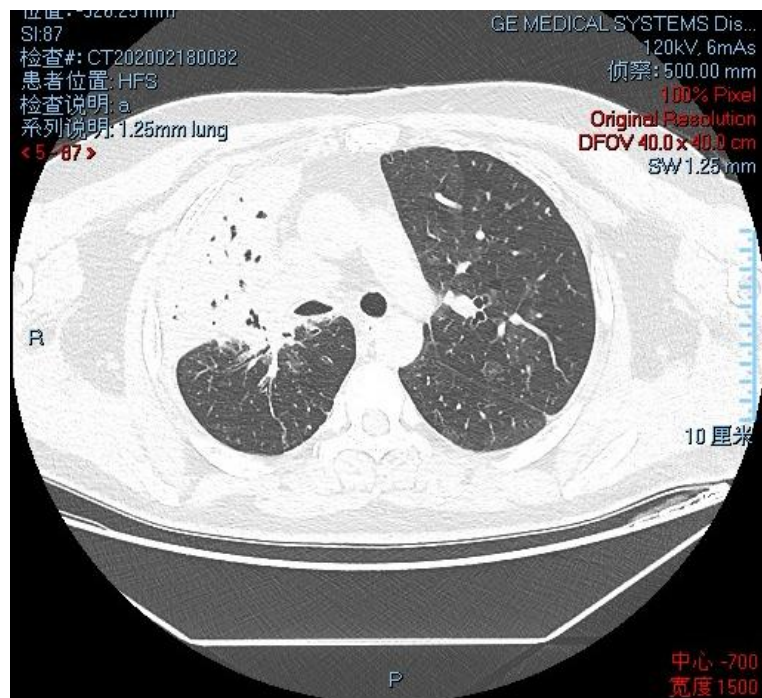


At 7 day

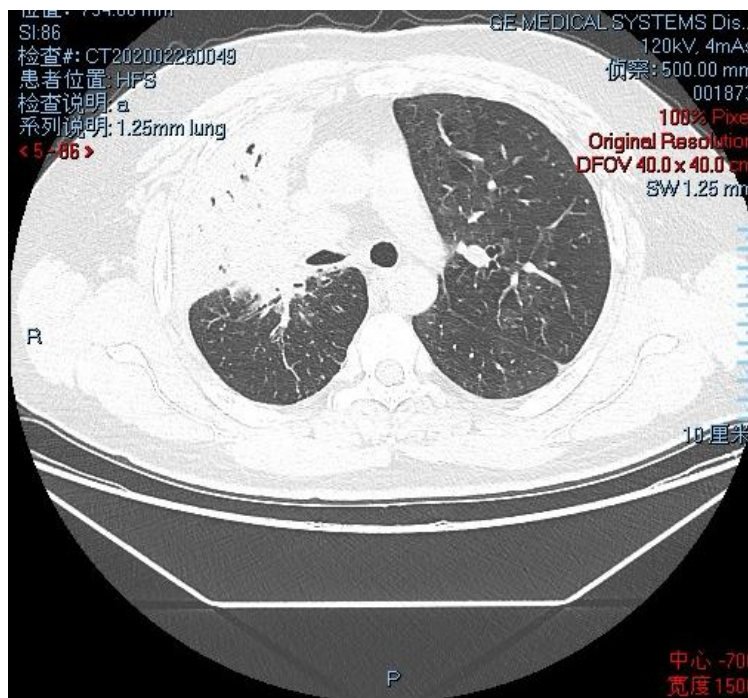


At 14 day

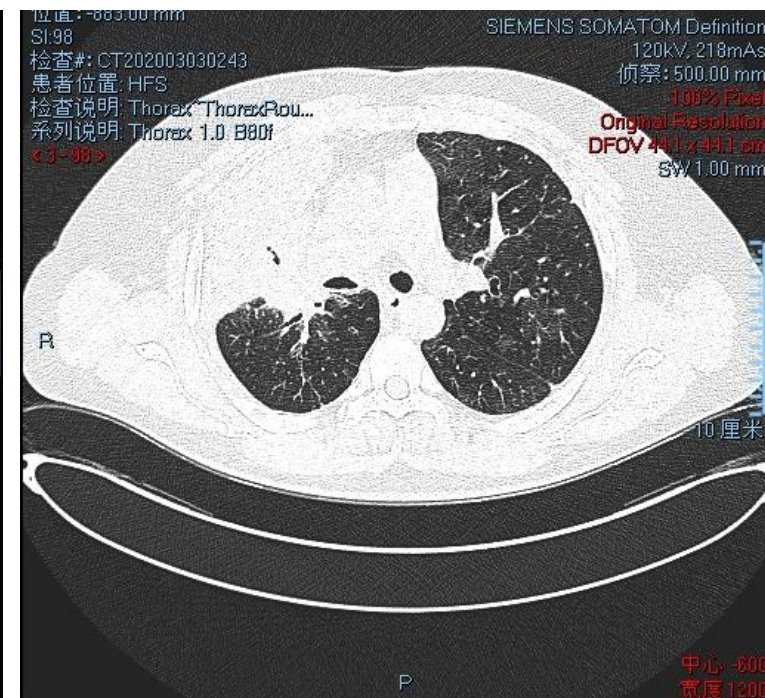
Patient 12 Control group



At admission

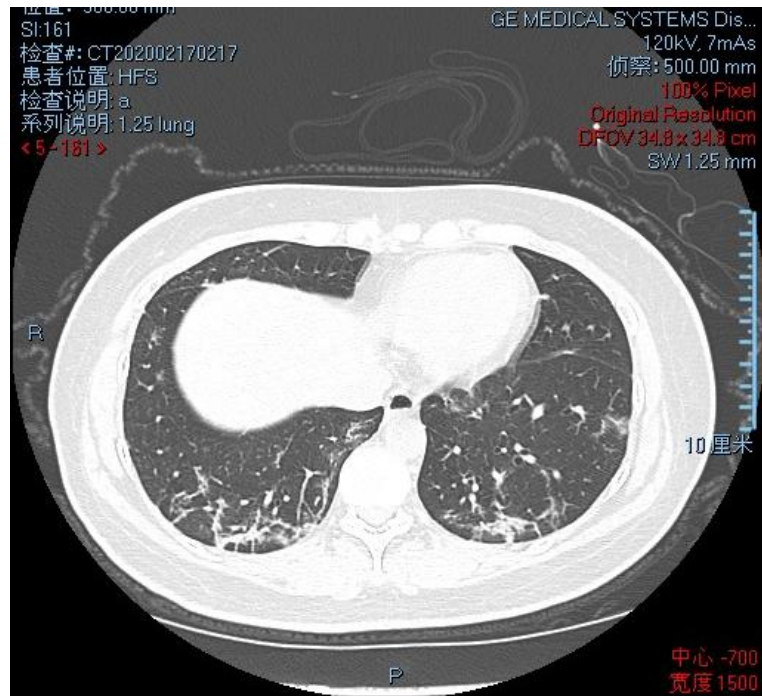


At 7 day

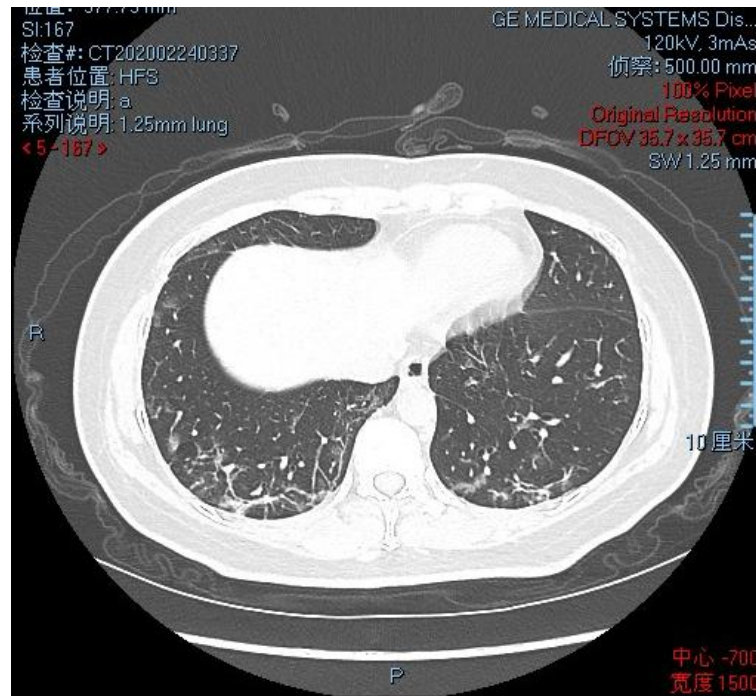


At 14 day

Patient 13 Control group

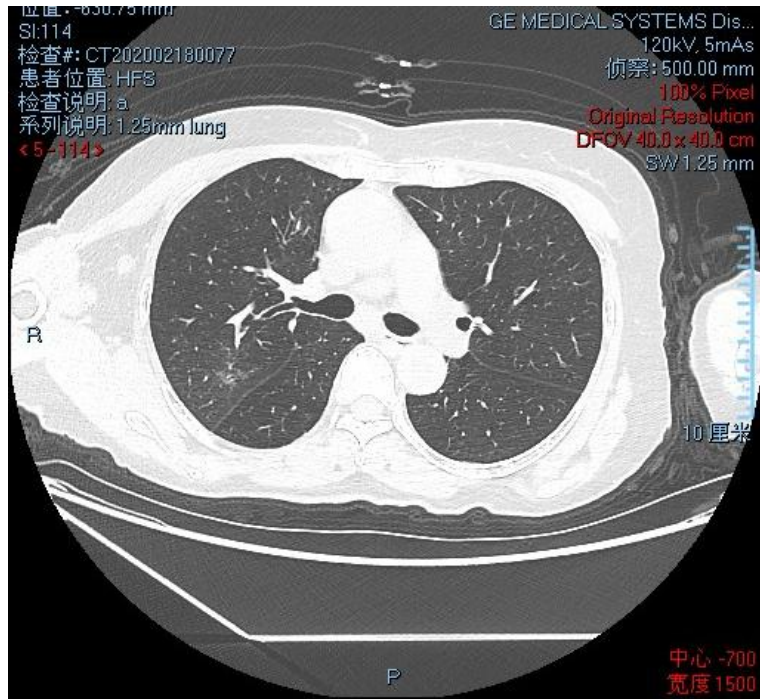


At admission

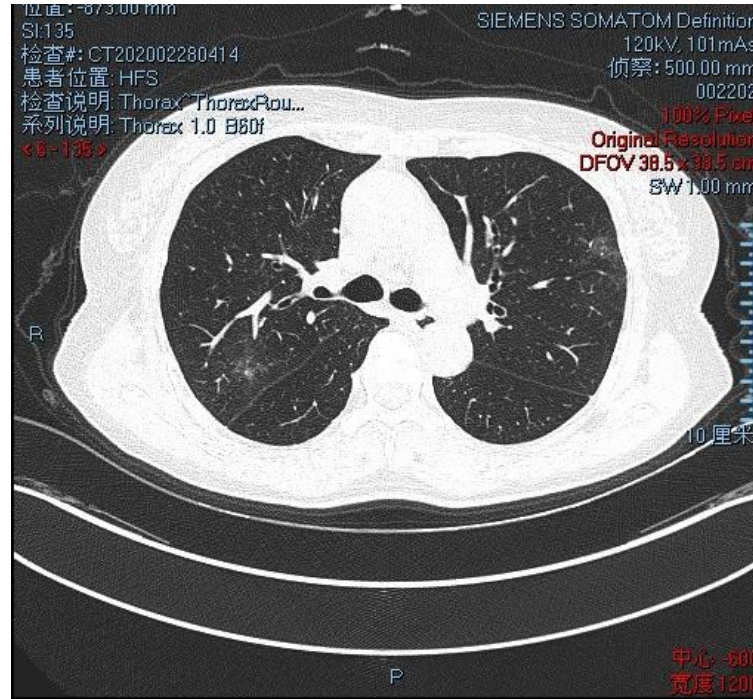


At 7 day

Patient 14 Control group

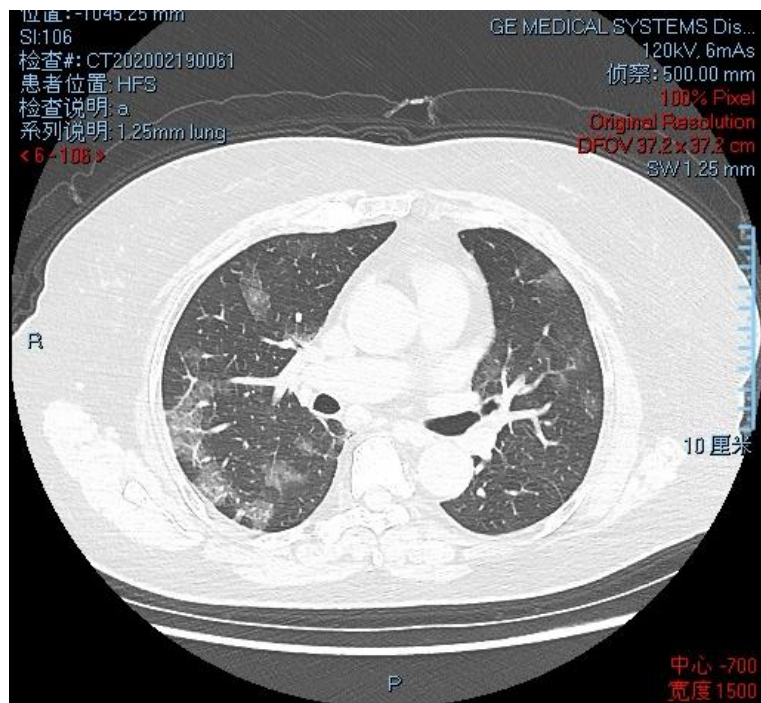


At admission

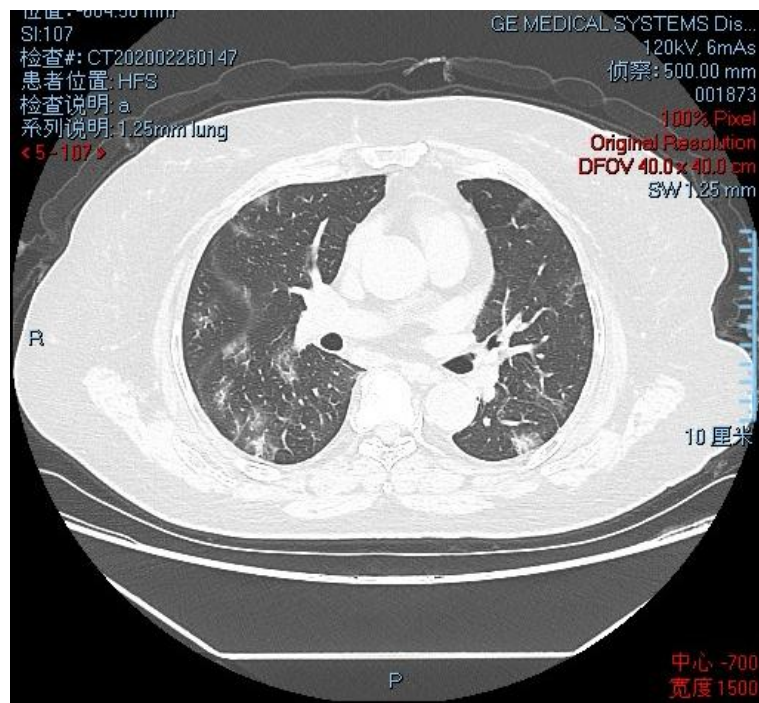


At 7 day

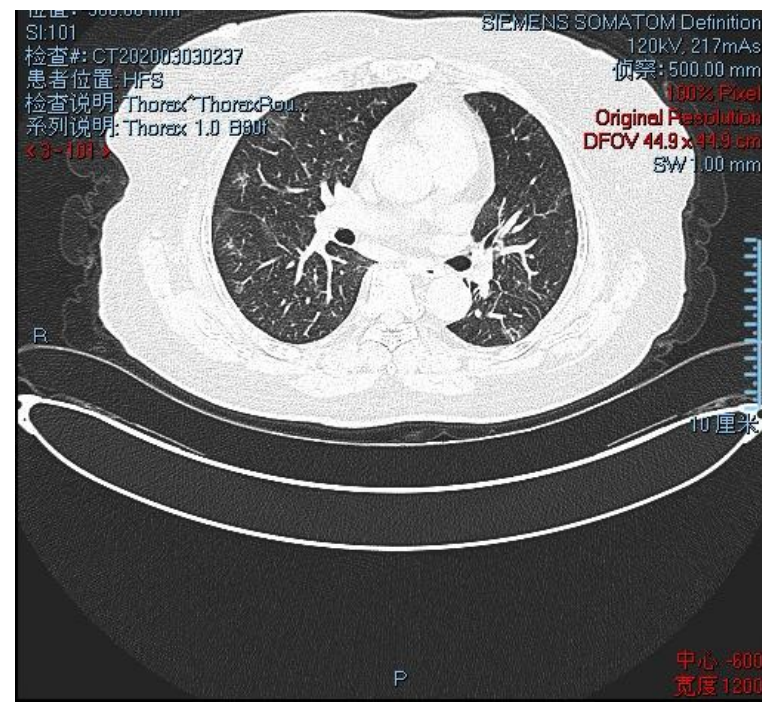
Patient 15 Control group



At admission

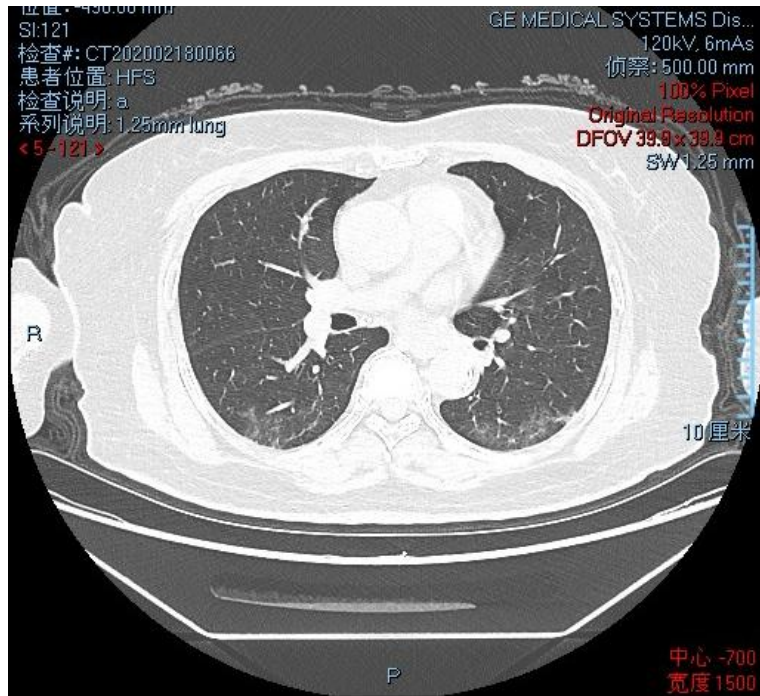


At 7 day

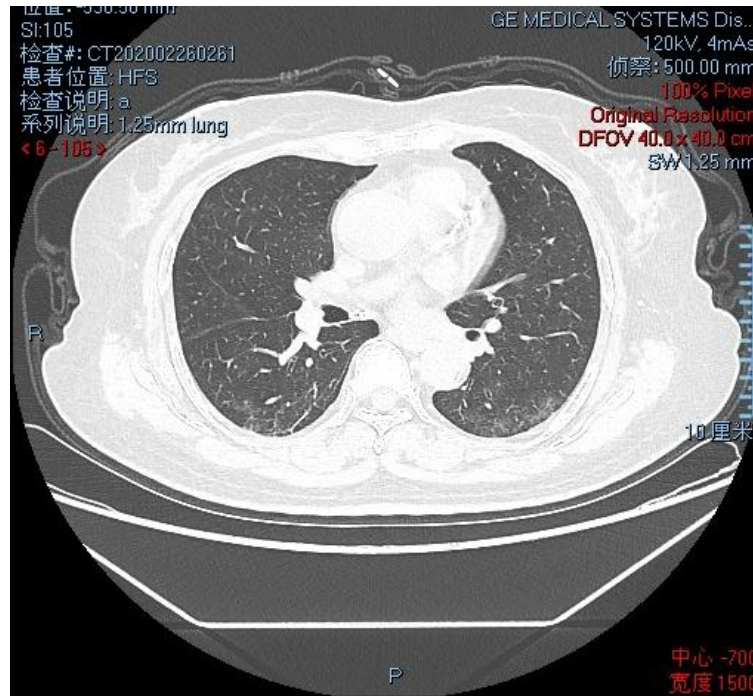


At 14 day

Patient 16 Control group

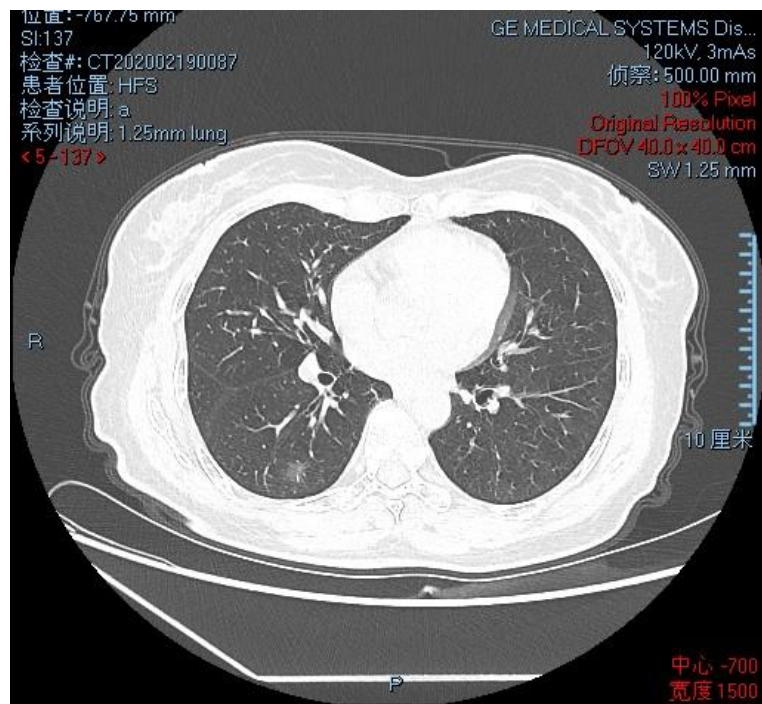


At admission

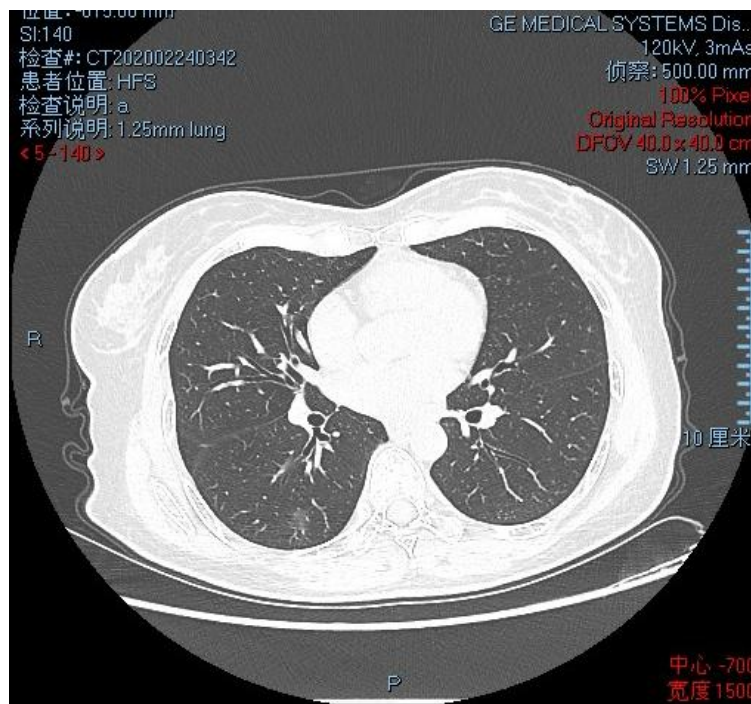


At 7 day

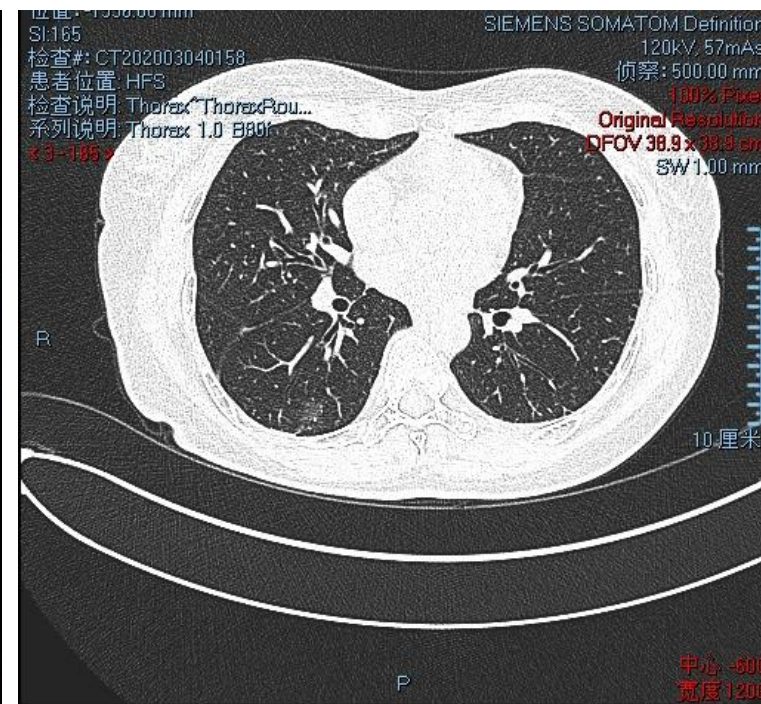
Patient 17 ^{99m}Tc -MDP group



At admission

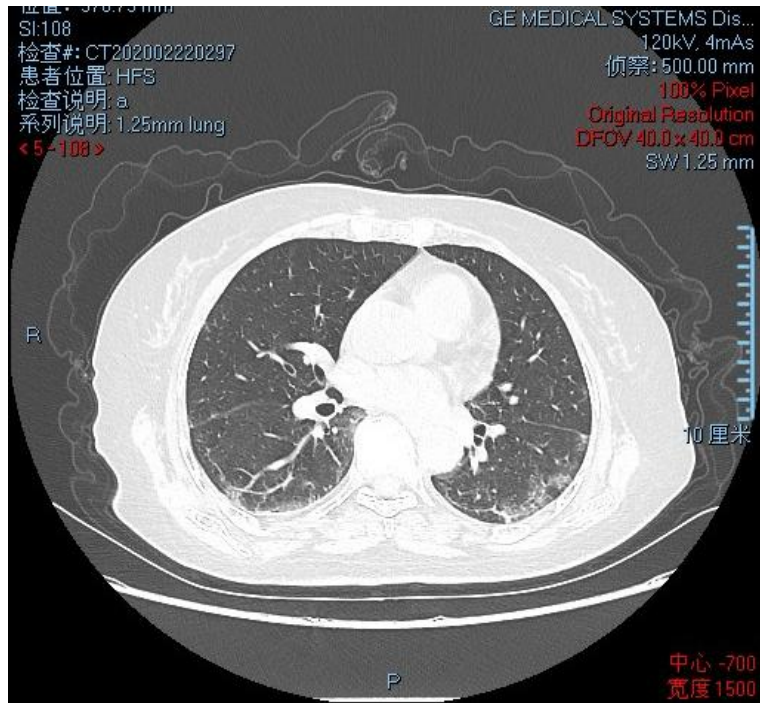


At 7 day

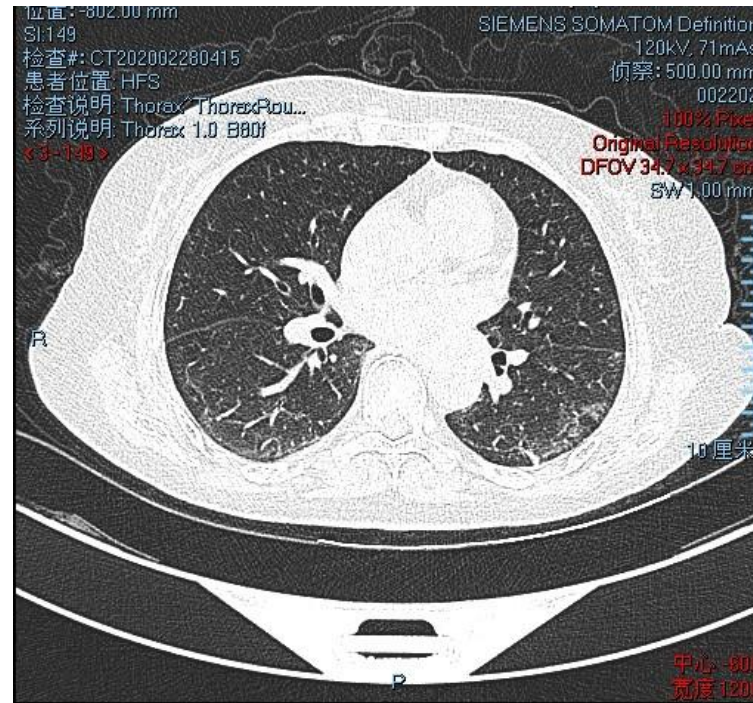


At 14 day

Patient 18 Control group

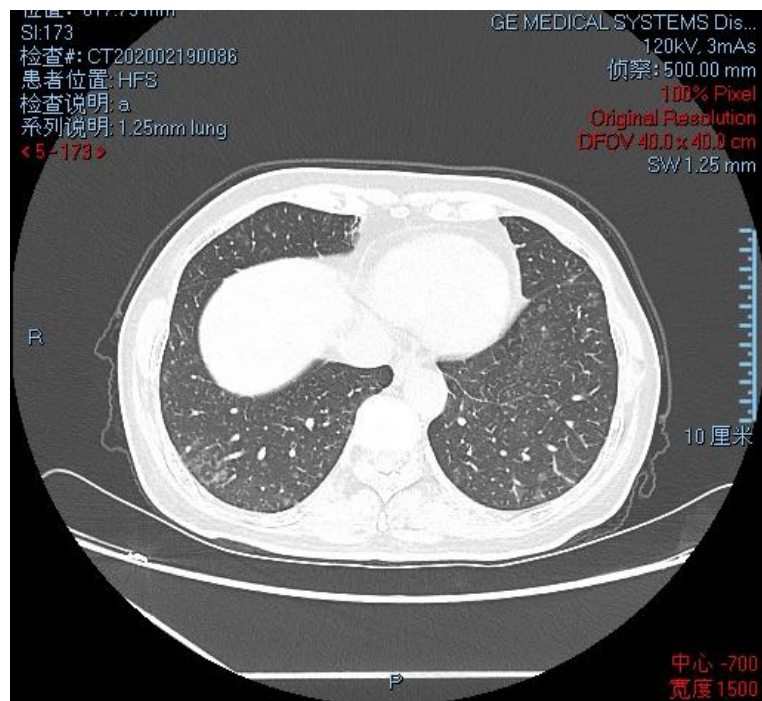


At admission

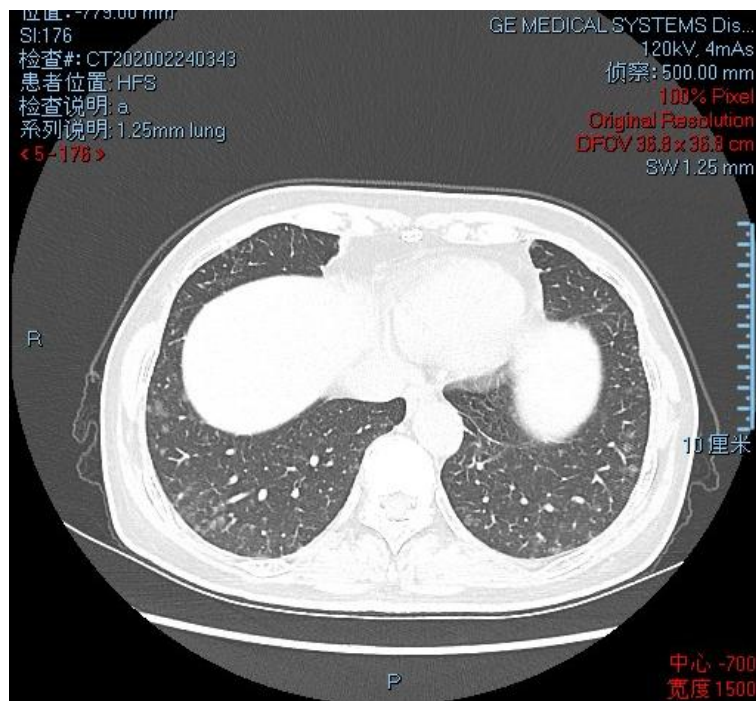


At 7 day

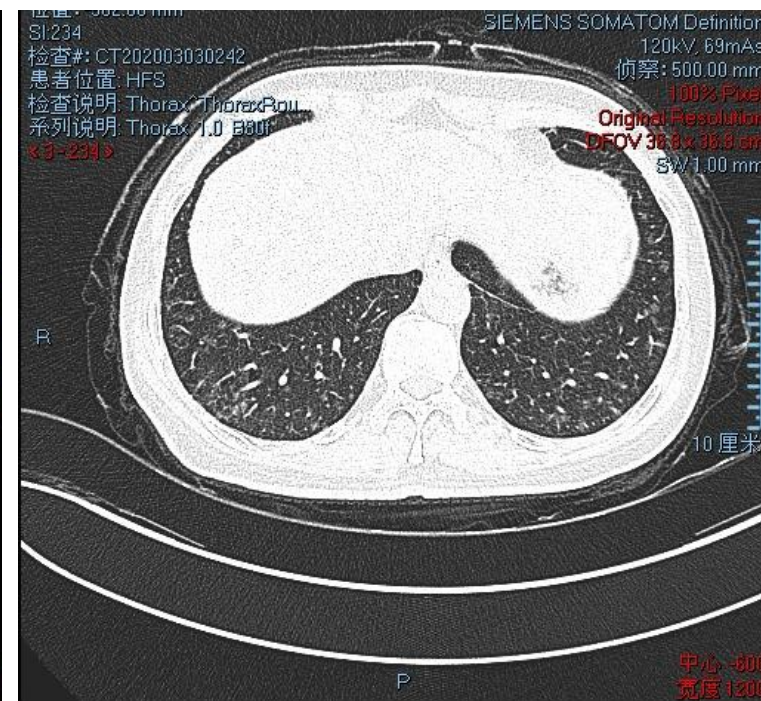Patient 19 Control group



At admission



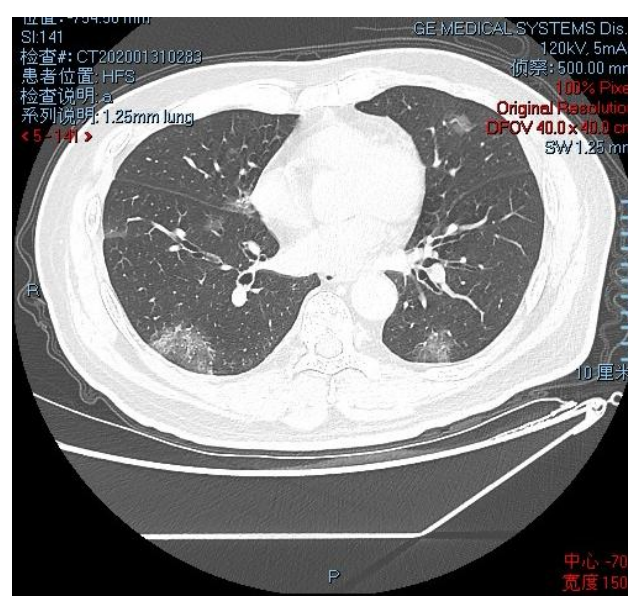
At 7 day



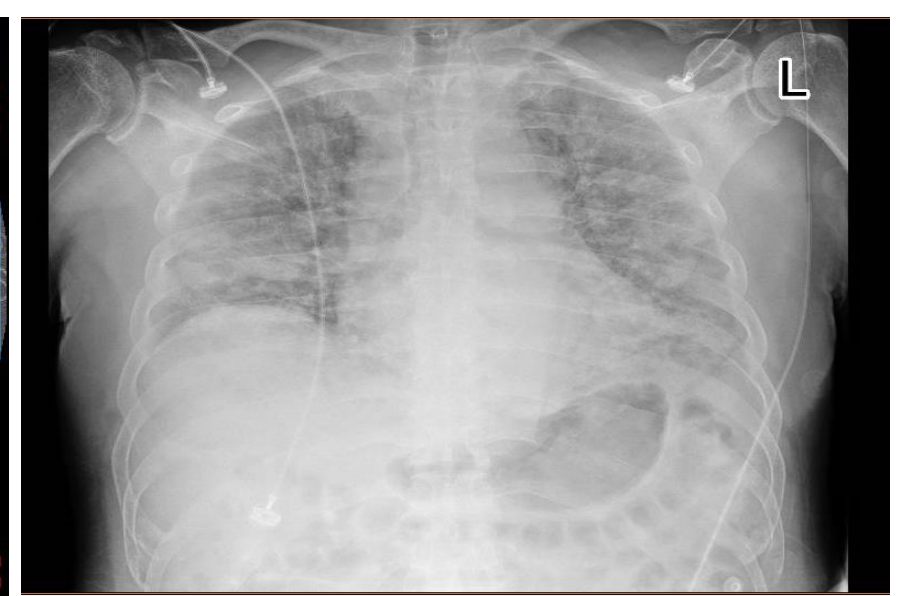At 14 day

Patient 20 Control group

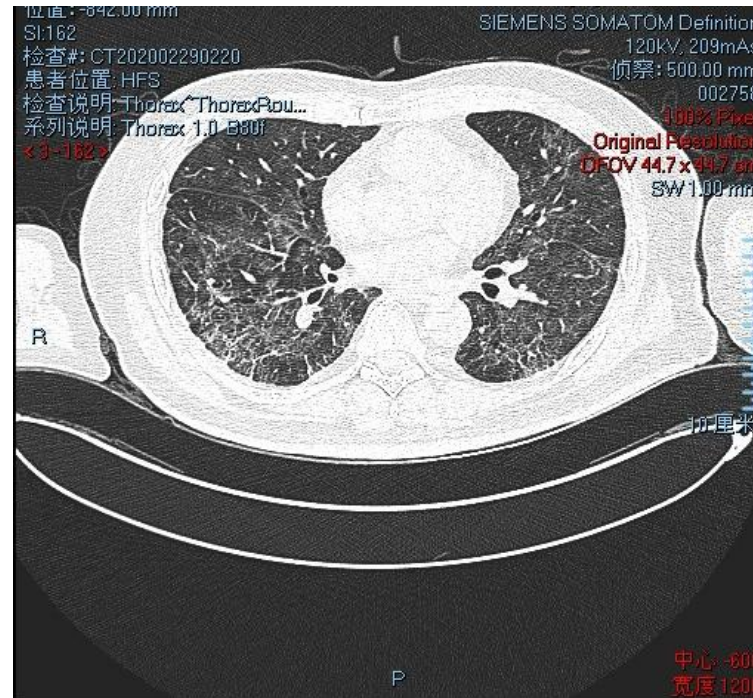
On January 31, the patient was admitted to the hospital for pulmonary CT. Due to the deterioration of the patient's condition, the patient could only take bedside chest x-rays on February 14. After that, the patient's condition improved, and the CT scans were performed on February 29 and March 6.



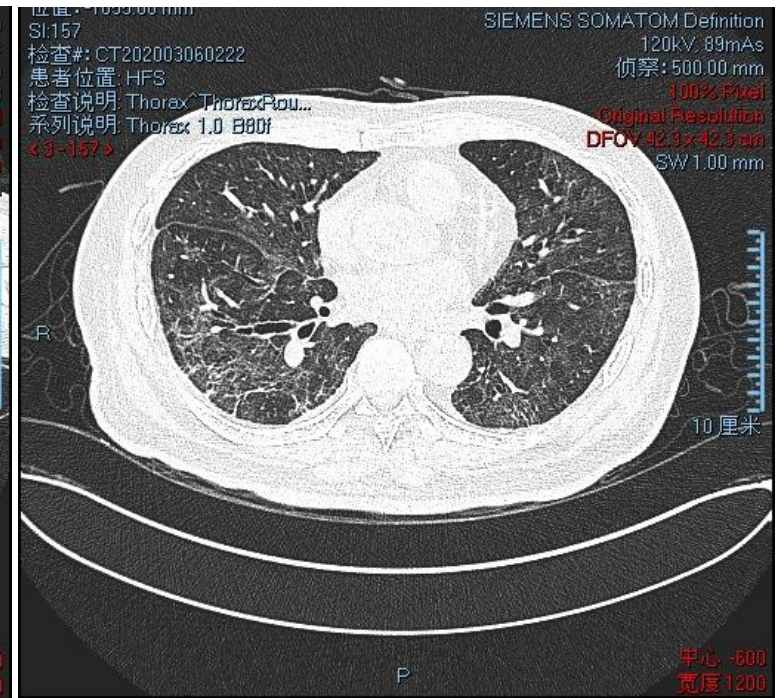
2020.01.31



2020.02.14

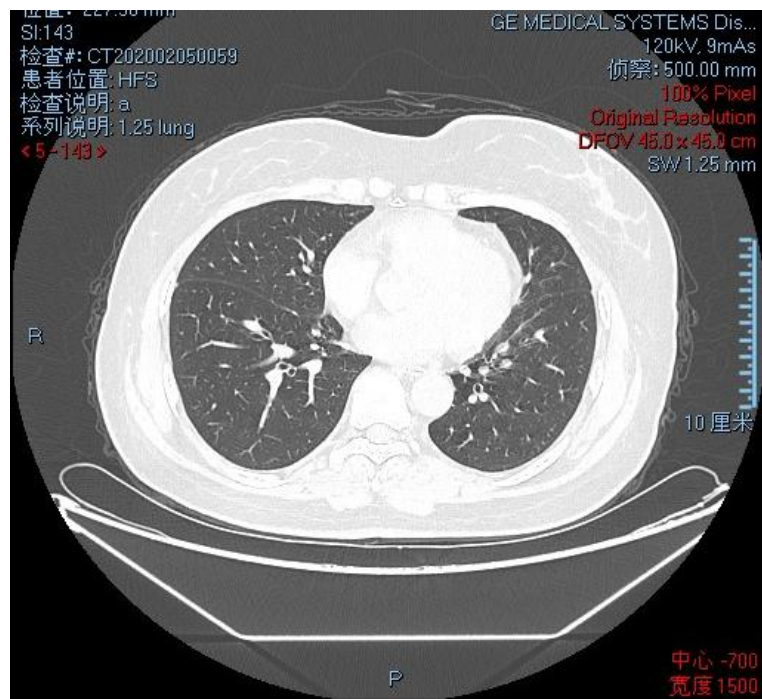


At 7 day(2020.02.29)

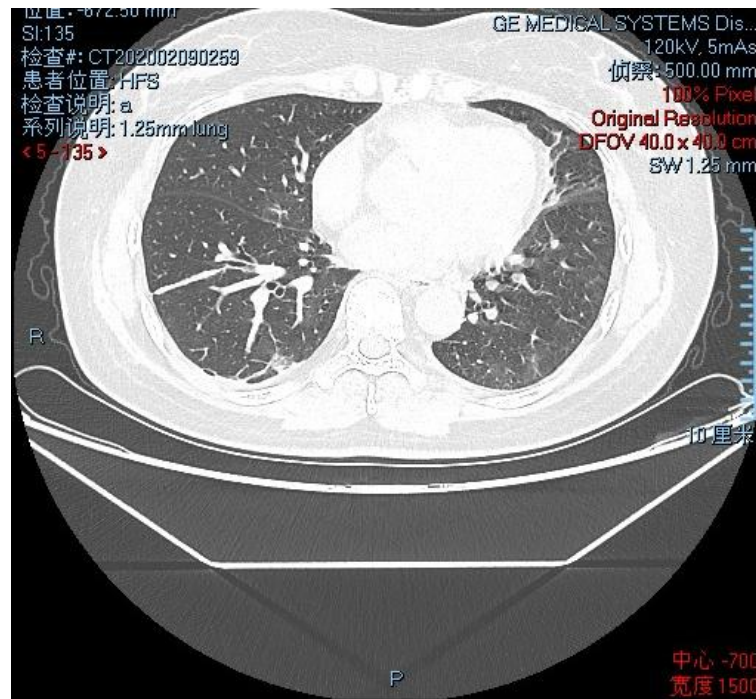


At 14 day(2020.03.06)

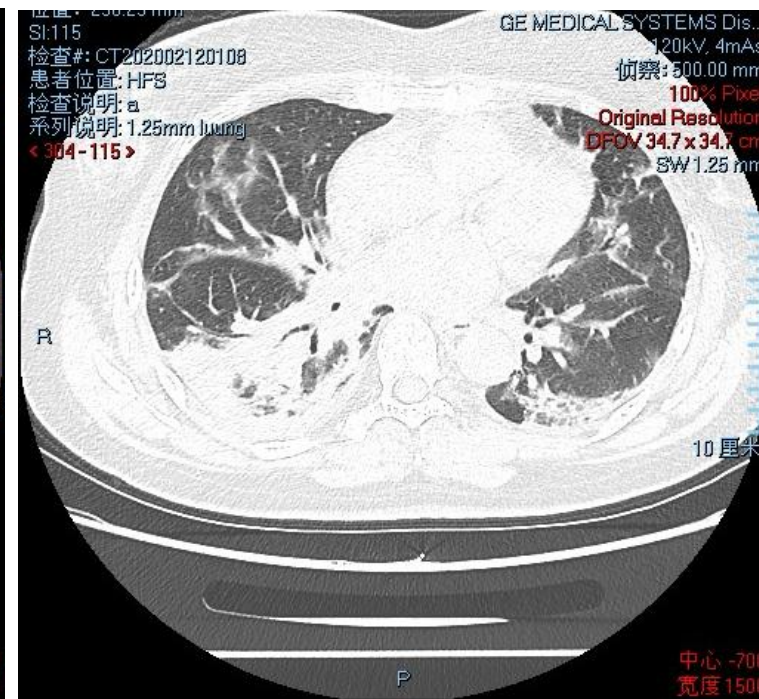
Patient 21 Control group



At admission



At 7 day



At 14 day